
Diseases of the
COLON & RECTUM

VOL. 11

July-August, 1968

No. 4

Anorectal Fistulas:

Current Concepts*

RAYMOND J. JACKMAN, M.D.†

Rochester, Minnesota

DIAGNOSIS and treatment of anorectal fistulas at times presents the simplest and at other times the most challenging problems encountered in surgery. Is this sinus actually an anorectal fistula? Or does it originate elsewhere, such as in a region of sigmoidal diverticulitis or ileocolitis? Or does it connect with an infected precoccygeal cyst? What keeps the sinus or fistula active when the primary source has healed over spontaneously or has been erased by a previous operation? In what situations might the surgeon anticipate fecal incontinence after fistulectomy, and what can be done about it?

The purpose of this presentation is to attempt to answer these and similar questions that, in my opinion, have been inadequately answered in medical literature. I shall not dwell on the simple uncomplicated fistula with a definite primary source

and secondary opening, since the principles of dealing with such a lesion have been well established.

Etiology

Anorectal fistulas comprise 85 per cent of sinuses opening onto the perineum. The other 15 per cent result from hidradenitis suppurativa, pilonidal disease, and other less common causes. There are many types of anorectal fistulas, but the one feature that they have in common is that they originated inside the anus or rectum. (I use the past tense because the anorectal site of origin, the primary lesion, may have healed over, but at one time it was present.) All anorectal fistulas and most perianal sinuses originate as abscesses. Frequently, but not always, the abscess starts as infection in a crypt at the mucocutaneous junction. Fistulas also may originate in a break in the continuity of the anal skin, such as a fissure, or in a break in the intestinal mucosa, such as an ulcer occurring in ileitis, ileocolitis, or ulcerative colitis.

* Presidential Address at the meeting of the American Proctologic Society, Denver, Colorado, June 10 to 13, 1968.

† Mayo Clinic and Mayo Foundation: Section of Proctology.

Differential Diagnosis

Sometimes determination of the exact nature and course of the fistulous tract has to be made when the patient is under anesthesia. The exploring finger is probably of more value than any other device in determining the source and course of the fistula. Frequently, the primary source can be palpated with the tip of the index finger as a depression or an area of induration. Bidigital examination, not uncommonly, will reveal a cord-like channel of induration leading to the secondary opening. Anoscopic examination may reveal a drop of pus exuding from the primary source or a tuft of granulation tissue. The use of the probe, until the time of operation, is probably the least effective means of determining the nature of the fistula and should not be resorted to if it causes the patient discomfort. The differential diagnosis of draining sinuses in the nether parts has been the subject of a previous presentation²

on unusual or less common causes of perianal sinuses, but the point I wish to make here is that a perianal sinus, ostensibly an anal fistula, for which the patient previously has been operated on, should alert one immediately to some unusual source—sometimes an infected precoccygeal cyst and, more frequently, regional ileitis or sigmoidal diverticulitis.

Association of Perianal Abscesses and Fistulas with Other Diseases: The tendency toward fistulization, not only anorectal but enteroenteric and so on, in ileocolitis has been noted by many authors. Rawls and co-workers,⁵ in a study of 1,000 patients with anorectal fistulas, found that 17 per cent of them had an underlying or associated systemic disease. The three disorders occurring most frequently were chronic ulcerative colitis, diabetes mellitus, and regional ileitis. In a study of 114 patients with regional enteritis, Smith and I³ have found that 1 per cent either had anal ab-

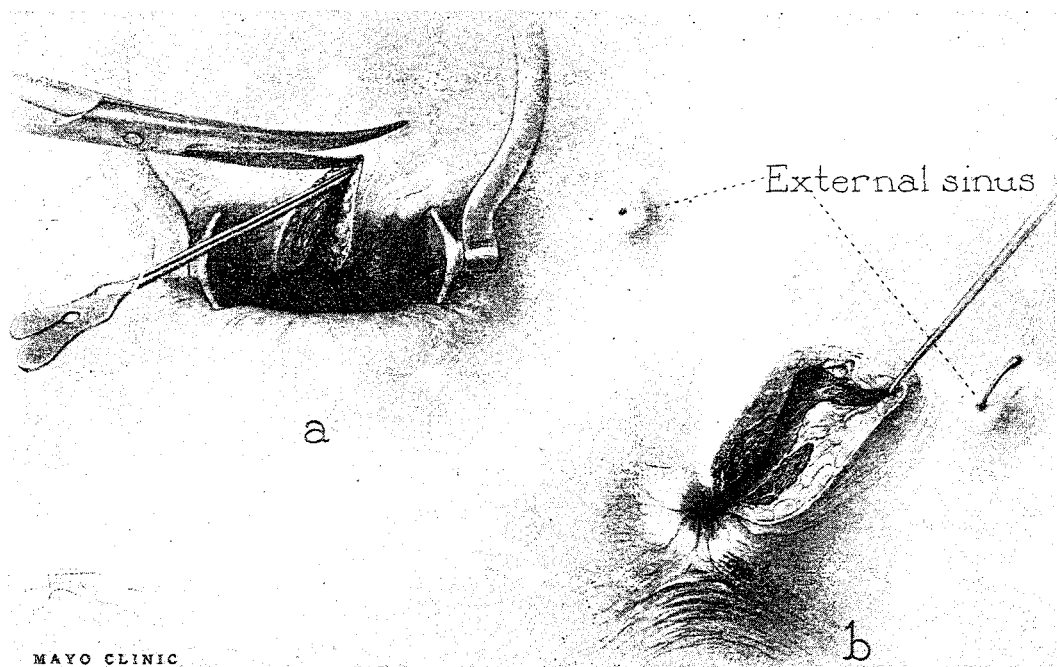


FIG. 1. *a* and *b*, Conversion of fistulous channel or tunnel into open ditch.

cess or fistula at the time of examination or gave a history of having had such a lesion in the preceding three years. Seven per cent of the patients in this group had a presenting complaint of anal fistula or abscess. The abdominal or gastrointestinal symptoms were so mild that the patients ignored them. *Any young adult whose presenting complaint is of anal abscess or anorectal fistula should be investigated for an underlying systemic disease, particularly for enteritis, enterocolitis (Crohn's disease) or ulcerative colitis.*

Association of Anal Fistula with Tuberculosis: Not too many years ago, the student was taught that if a patient was found to have an anorectal fistula, one should look for a focus of tuberculosis elsewhere in the body, either pulmonary or gastrointestinal. This teaching no longer holds true. In fact, many patients previously considered to have intestinal tuberculosis probably had granulomatous ileocolitis. Since the advent of chemotherapeutic drugs and antibiotics — para-aminosalicylic acid, isonicotinic acid, streptomycin, and so on — the incidence of tuberculosis, while still a public health problem, has declined markedly. This is particularly true of anorectal tuberculosis and tuberculous fistula. In an article published in 1939, Buie, Smith, and I¹ reported the results of an intensive study of 600 patients with anal fistula. Of these patients, 11.5 per cent were found to have tuberculosis some place in the body. Using guinea pig inoculation and histologic study of the excised fistulous tracts, we determined that about 8 per cent of anal fistulas were tuberculous, and that in most of these cases there was an active or healed pulmonary focus. I am certain that the percentage of tuberculous fistulas would be much less today. During the past two years I have diagnosed definitely only one case of tuberculous fistula. The diagnosis was confirmed by guinea pig inoculation and histopathologic study.

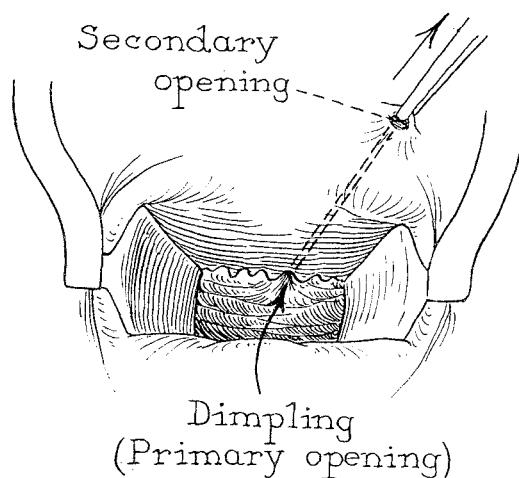


FIG. 2. Traction applied to site of secondary opening and consequent retraction at primary source. This procedure usually gives a clue to the location of the primary lesion.

Association of Anal Fistula with Cancer: Cancer developing in or near chronic draining sinuses, although uncommon, has been reported many times. In such instances the fistulas usually will have been present for many years. It is generally contended that irritation plays an important part in the development of certain cancers. Perhaps the carcinogenic mechanism in the case of anal fistula is the long-continued drainage.

Kline and co-workers⁴ reported five cases of long-term anal fistula in which a carcinoma developed later. They collected 20 other similar cases from medical literature, and concluded that the difficulty in diagnosis of this complication of anal fistula resulted mainly from the insidious nature of the tumor and the masking effect of the symptoms of the fistula on the early symptoms of cancer. Of the 25 tumors, 44 per cent were mucus-producing adenocarcinomas of low-grade malignancy. In one of their five cases from this clinic, the patient had had a fistula-in-ano for 47 years before an adenocarcinoma was detected. A radical surgical operation is indicated for carcinoma superimposed on a fistula.

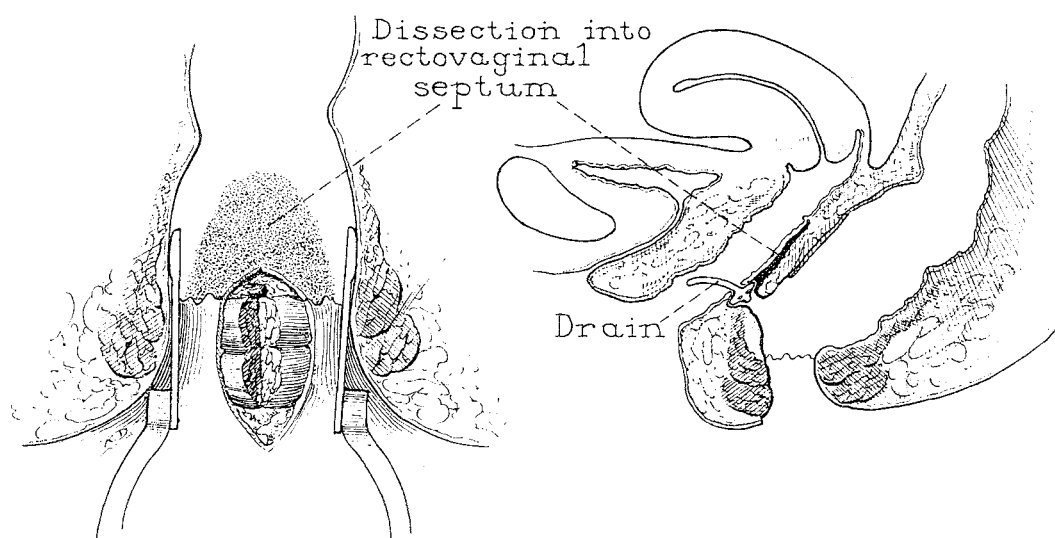


FIG. 3. Operation for rectovaginal fistula. Undercutting rectovaginal septum mobilizes it sufficiently so that it can be pulled down and sutured to the inner border of the external sphincter after drain has been placed beneath the septum and out through the fistulous tract. (From Jackman, R. J.: Rectovaginal and anovaginal fistulas: A surgical procedure for treatment of certain types. *J. Iowa Med. Soc.* 42:435-440 [Sept.] 1952. With permission of the Iowa Medical Society.)

General Aspects of Treatment

The use of antibiotics in the treatment of anorectal abscesses and fistulas is not advisable because usually incision and drainage has to be carried out anyway. Although *Escherichia coli*, the usual offending organism, is vulnerable to tetracycline, administration of this antibiotic will not resolve the problem and operation will be necessary regardless. If the abscess is the initial sign of a true fistula, which it usually is, a primary source inside the anus or rectum continues to exist and is not affected by any antibiotic.

The basic principle involved in all operations for anorectal abscess or fistula is that satisfactory drainage must be established. On the face of it this sounds simple, but the operations for fistula may be extremely difficult and the convalescence prolonged. On the other hand, such operations may be very simple. If the problem is uncomplicated—a primary opening within the anal canal and a secondary opening in the perianal skin—a probe is passed from the pri-

mary out through the secondary opening; the overlying tissue is incised, converting the fistulous channel or tunnel into an open ditch; and debridement of the wound margins is accomplished (Fig. 1).

Obviously there are many deviations from the "straightforward" fistula, and combinations of two or more fistulas may occur, but the basic aim of surgical treatment in all cases is to establish adequate drainage. During the operative procedure, the surgeon must ask himself, Will the drainage be satisfactory when the tone of the muscle returns or will there be overhanging ledges or pockets that will interfere with drainage? If the latter appears more likely, steps must be taken to correct this by debriding the margins more extensively or by incising muscle.

Finding the Primary Source of the Fistula: Sometimes this may be difficult. If the lesion is a fistula, there is, or at one time was, a primary or internal opening. If the patient has had a previous operation, the landmarks may be distorted and the

source of the fistula difficult to find. A fistula may remain active even though the primary source has healed over, being perpetuated by the inflammatory granulation tissue in the channel or abscess cavity.

Use of dye: Many surgeons use dye to determine the course of the channel and to find the primary opening. My own experience with this method has been quite unsatisfactory; furthermore, in my opinion, it is unnecessary, since the contrast between the channel or tract itself with its infected granulating wall and the fresh adjacent normal tissue is quite striking. The use of dye disguises this picture and tends to obscure the whole field.

Bidigital examination: While the patient's muscles are relaxed during anesthesia, bidigital palpation of the regions of induration probably is the best method for finding the source and course of the tract.

Traction on the secondary opening: This procedure (Fig. 2) will sometimes cause retraction or dimpling at the primary source of the fistula.

Probing the tract: Ideally, one should attempt to probe from the primary opening out through the secondary opening. However, probing from the secondary opening sometimes will reveal the internal or primary source. One may need to bend and shape the malleable probe to accommodate it to the course of the channel.

What Does the Surgeon Do When It Seems Impossible to Find a Primary Source? The patient may or may not have been operated on previously, the anus is smooth and scarred, landmarks are absent, and the probe can be inserted into the sinus up to or near the site where you think the primary source should be. Assuming that usual causes for the sinus have been ruled out, is it adequate to lay all the tissue overlying the probe open, curette the tract, and pack it? Although this may work in some instances, I think it is best

to incise the muscle at the site where you think the primary source should be. In my experience, this is particularly true for fistulas presumed to originate posteriorly, less true for anterior and lateral fistulas. I do not have a completely adequate explanation of why this is necessary; but I do know that time and again when I have not done it, patients have had further trouble. Perhaps the intact anal muscle prevents adequate drainage during healing.

Specific Surgical Problems

Fistulotomy Versus Fistulectomy: In my opinion a fistulectomy is preferable to a fistulotomy for the following reasons: 1) When the fistulous tract is excised (fistulectomy), one occasionally will discover a hidden channel or offshoot from the main tract, which otherwise would not have been found. A spot of granulation tissue remaining along the course of the excised fistulous tract should alert one to the possibility of an offshoot or abscess cavity. 2) By doing a fistulectomy, one removes the occasionally-epithelized tract or the infected granulating tract, leaving a fresh-wound sulcus that seems to heal faster and to form a narrower scar. When a wide block of scar tissue forms, the anal muscle becomes mechanically less efficient and there may be "leakage" or difficulty in holding gas.

I realize it is sometimes poor judgment even to attempt a fistulectomy. In a very deep-lying channel, not only may excision of the scarred granulating tract be impossible, but attempted excision may be mutilating and may create fecal incontinence or an inefficient anus. If a fistulectomy cannot be done, or if it is thought inadvisable, granulations in the channel should be scraped away with the blade of the scalpel or wiped away with gauze.

Simultaneous Abscess Drainage and Fistulotomy: Are drainage of the abscess and a definitive operation for the resulting fis-

tula feasible simultaneously? The answer varies with the circumstances.

If the abscess is relatively superficial and the primary source readily discernible, drainage and fistulotomy may be carried out at the same time. This has obvious advantages when it can be done. Only one hospitalization period and one anesthetic are necessary, and convalescence is shortened.

If the abscess is deeply situated, very large, or of questionable extent, it is better initially to establish drainage and subsequently to perform a delayed fistulectomy or fistulotomy. It has been my experience that when I have tried the complete procedure under such circumstances, I have overlooked a loculation of the abscess that would require another operation later. Also it seems that a wider scar forms from the acutely infected wound, resulting in leakage and inability to control flatus.

Treatment of Anorectal Fistulas Presenting Special Problems: *Low-lying anterior fistulas:* Certain fistulas—such as anovaginal, rectovaginal, and some anterior perineal fistulas—sometimes require special surgical procedures. Most of these low-lying anterior fistulas resemble other fistulas in this region—that is, they originate from infection in a crypt and they involve abscess formation; they differ in that the secondary opening occurs inside the vagina or near the vagina on the perineum. The usual unroofing or conversion of the tunnel into an open ditch might result in fecal incontinence in certain cases and require a secondary repair. Low-lying anterior fistulas that underlie little muscle are treated the same as any other fistula, by simple unroofing. However, when the opening at the source of the anorectovaginal fistula is just proximal or distal to the dentate margin and the vaginal opening is just inside the posterior fourchette, my colleagues and I have used the following procedure with good results: 1) The patient is placed in

the prone “jackknife” position—that is, with the hips slightly elevated. 2) With a Smith operating anoscope in place, a curved incision is made in the anterior anal wall, just distal or external to the source or anal opening of the fistula. 3) The rectal mucosa, submucosa, and muscularis (about half of the thickness of the rectovaginal septum) are undercut for 2 to 3 cm proximal to the fistula (Fig. 3). 4) The anal skin (with hemorrhoids, if any) overlying the anterior anal wall is excised, exposing the anal muscles. 5) One end of a small rubber drain is sutured beneath the undercut septum with catgut, the free end extending through the fistulous opening into the vagina (Fig. 3). 6) About a third of the thickness of the anal musculature on the anterior wall is incised to eliminate an overhanging ledge which could block drainage. 7) The undercut septum or flap is sutured with interrupted silk sutures to the inner edge of the external sphincter; to prevent cutting through the tissue it is important that the flap have little or no tension on it and that sutures not be tied too tightly (Fig. 4).

The advantage of this procedure is that with the two-way drainage—primarily through the drain under the septal flap and secondarily by way of the partial incision of the sphincter muscles—the possibilities of infection and accumulation of serum, blood, or pus beneath the flap are eliminated. The partial severance of the anal musculature distal to the suture line, in addition to contributing to the drainage, eliminates any overhanging ledge, thus preventing tension or pressure on the suture line. After two or three weeks, the severed ends of the musculature are pulled together by scar formation, and continence is restored.

A minimal-residue diet is prescribed postoperatively, and measures are instituted to prevent bowel movements for about a week. The rubber drain is removed after three

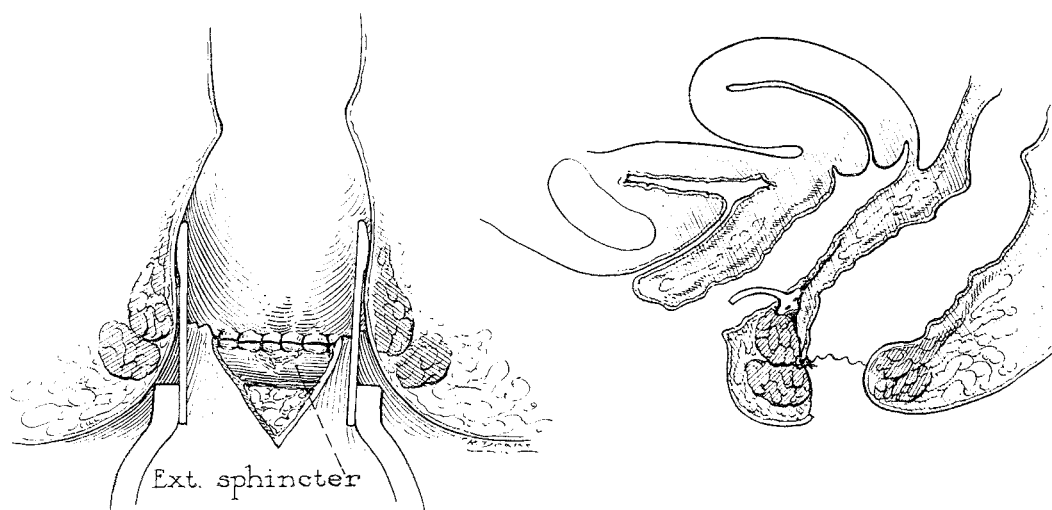


FIG. 4. Completed operation for rectovaginal fistula. The mobilized septal flap has been sutured in place. (From Jackman, R. J.: Rectovaginal and anovaginal fistulas: A surgical procedure for treatment of certain types. *J. Iowa Med. Soc.* 42: 435-440 [Sept.] 1952. With permission of the Iowa Medical Society.)

days, and the sutures are removed after eight days.

In selected cases of anorectovaginal fistula this procedure has a high degree of success, even in the presence of quiescent colitis or enteritis. If the tract through the perineal body is tortuous or is draining pus actively, unroofing with subsequent perineal repair probably is best.

Anorectal fistula associated with ulcerative colitis and regional enterocolitis: In general, elective anorectal surgery is unwise in cases of active ulcerative colitis. The resulting wounds are slow to heal and very painful, and postoperative care is unsatisfactory because of frequent rectal discharge. Surgical operations on these individuals actually seem to make the colitis worse in some instances. Anorectal abscess and fistula are serious complications of ulcerative colitis, which often start a chain of events that may lead to ileostomy and colectomy. They comprise one of the most common complications of ulcerative colitis, about 8 per cent to 10 per cent of patients being afflicted. If a patient with ulcerative colitis has an anorectal abscess, the incision for

drainage should be generous, in the hope that the wound will stay open longer.

During a remission or an inactive phase of the colitis, operation sometimes is advisable to prevent a simple fistula from becoming more complicated, but even then it is frequently difficult to decide to operate because wound healing may be very slow.

The tendency to fistulization in granulomatous enterocolitis is well known and, as indicated previously, the anal fistula may be the main complaint of some individuals whose intestinal symptoms are mild or minimal. Operation for anorectal fistula is not always contraindicated in cases of enteritis, but usually the wound heals slowly.

Fecal Incontinence, Leakage, and Difficulty in Holding Flatus after Operation for Fistula: Difficulty in controlling bowel movements seldom presents a long-term problem after operation for anorectal fistula. On the other hand, such difficulty is frequently a temporary problem until the wound has had a chance to heal and the wound margins have pulled together. The individual who has an irritable bowel or erratic bowel habits with bouts of diarrhea

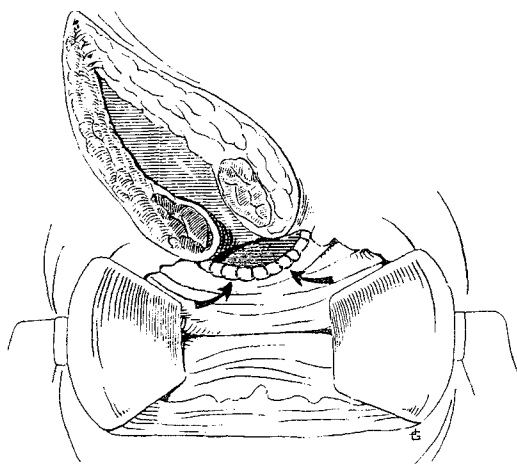


FIG. 5. Excisions of zone of mucosa at the proximal end of the fistulous wound. This helps obviate leakage of mucus when healing is complete.

and constipation is apt to have the most trouble of this sort; consequently, one usually can predict preoperatively those patients who may and those who may not experience leakage. Certain deep-lying anterior fistulas are more apt to result in incontinence than are posterior or lateral fistulas. For some of these individuals, particularly those having an irritable bowel syndrome and episodes of diarrhea, I have eradicated the lesion by denuding the area of the primary source, covering the denuded area with a flap, and coning out the fistulous tract down to the primary source. In general, however, the surgeon must keep in mind that to cure the fistula he must convert the tunnel into an open ditch regardless of how much muscle must be incised to accomplish this. It is also important to find out and record preoperatively if the patient has any difficulty with control. Many times I have observed patients who are completely incontinent who have never had an anorectal operation but have had a long-standing fistula with many recurring abscesses. The repeated insults of the abscesses and resulting scar formation have immobilized and destroyed the anal-sphincter mechanism completely.

Use of the seton: The seton is used widely in European countries, and to a lesser extent in America, principally on patients whom the surgeon thinks may have difficulty with fecal incontinence if orthodox fistulectomy is performed. Its proponents think the gradual process of cutting through the sphincter with the seton permits the scar to form back of the ligature, thus holding the ends of the muscle fibers together. Personally, I have never used the seton in operations for fistula. It is true that a small percentage of patients have some temporary difficulty with fecal control. It is also true that a very small percentage need a secondary repair such as a perineorrhaphy, but it has been my observation that this is sometimes necessary whether or not a seton is used.

Preoperative, operative, and postoperative measures to avert or ameliorate incontinence: Preoperatively, it is well to inform patients having an irritable bowel or healed ulcerative colitis that there may be some temporary difficulty with control after operation and that a secondary repair may be necessary later. At the time of operation, or earlier, the surgeon must determine whether to excise the fistulous tract (fistulectomy). Especially when there is much scar tissue, fistulectomy tends to create a wound that can unite or pull together more satisfactorily than can the wound produced by a lesser procedure, thus reducing the likelihood of incontinence. In certain other cases, especially where the fistula is deep-lying, the decision to perform a fistulotomy rather than a fistulectomy may reflect better judgment.

During either operation, I frequently excise a piece of rectal mucosa shaped like a half-moon (Fig. 5) proximal to the primary source. I think this enables that part of the wound near the rectum to pull together better; also, there is less apt to be leakage of mucus after healing is complete.

Postoperatively, any packing placed in

the wound should be removed within 24 to 48 hours. Long-continued packing of the wound is undesirable since it creates a wide block of scar which makes the sphincter mechanism less efficient.

When fecal incontinence is a problem postoperatively, some patients may need to perform anal muscle exercises, take anticholinergic drugs, and eat minimal-residue diets.

Comment

Certain rules, not completely inviolable, may be laid down in regard to the diagnosis and treatment of anorectal fistulas.

1. Anorectal fistulas and abscesses occurring in young adults should arouse suspicion of an associated enteritis or enterocolitis.

2. The "much-operated-on" persistent anorectal fistula should make one think of an unusual cause such as an infected precoccygeal cyst.

3. Antibiotic therapy does not cure anal fistulas.

4. The basic principle of all operations for anorectal fistula is adequate drainage.

5. Anal fistulas may remain active even though the primary source has been obliterated if drainage is inadequate or if infected granulation tissue remains in the channel.

6. One should be able to predict preoperatively, with a fair degree of accuracy, those individuals who are apt to have difficulty with fecal control after operation for fistula. For such individuals, those having irritable-bowel syndrome or a diarrheal tendency, an alternative procedure or a secondary repair should be planned in advance.

References

1. Buie, L. A., N. D. Smith, and R. J. Jackman: The role of tuberculosis in anal fistula. *Surg. Gynec. Obstet.* **68**: 191, 1939.
2. Jackman, R. J.: Perianal sinuses: Some unusual causes. *Dis. Colon Rectum.* **8**: 115, 1965.
3. Jackman, R. J., and N. D. Smith: Some manifestations of regional ileitis observed sigmoidoscopically. *Surg. Gynec. Obstet.* **76**: 444, 1943.
4. Kline, R. J., R. J. Spencer, and E. G. Harrison: Carcinoma associated with fistula-in-ano. *Arch. Surg. (Chicago)*. **89**: 989, 1964.
5. Rawls, W. E., W. J. Martin, R. J. Spencer, and H. N. Hoffman: Perianal abscess and anorectal fistula. *Minnesota Med.* **46**: 327, 1963.

Memoir

BELT, ROBERT LEROY, Glendale, California; born Wellsville, Tennessee, March 3, 1899; Rush Medical College, 1924; internship Los Angeles General Hospital 1924-1926; served with U. S. Armed Forces in World War I.

Dr. Belt joined the American Proctologic Society in 1941 and was elected to Fellowship in 1948. He was a Fellow of the American College of Surgeons and a member of the American Medical Association, California Medical Association and Los Angeles County Medical Association; on the staffs of Memorial and Behrens Hospitals, Glendale, and St. Joseph's Hospital, Burbank; Emeritus Associate Clinical Professor of Surgery, U.S.C. Medical School. Dr. Belt died February 25, 1968.