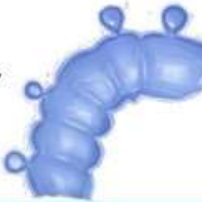

Clinical Practice Guidelines: Left-Sided Diverticulitis (1/2)



CT scan best initial diagnostic imaging test (1B)



Uncomplicated mild disease can be treated **WITHOUT** antibiotics (1A)



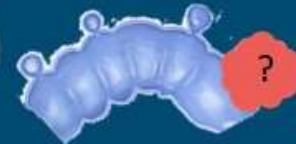Percutaneous Drainage for Abscess > 3cm in size (1B)



Recommend Elective Surgery after **complicated** disease e.g. abscess treatment or if fistula, stricture (1B)



Endoscopic evaluation recommended to confirm diagnosis (1c)



0.7-11% risk of malignancy

Individualized decision for surgery in Uncomplicated disease based on risk (1B)



NNT=18 elective to prevent 1 emergency surgery



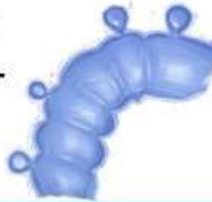DISEASES OF THE COLON & RECTUM



Hall J et al. *Dis Colon Rectum* 2020;63(6):728-47



Clinical Practice Guidelines: Left-Sided Diverticulitis (2/2)



Urgent Surgery if peritonitis or failure of medical treatment (1c)

15-30%



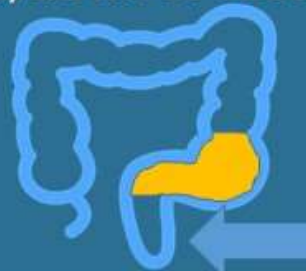Young Age at index presentation → surgery **not** recommended (1c)



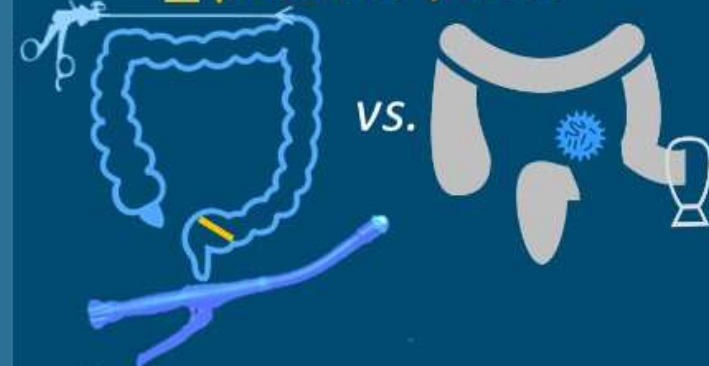
Lap Lavage not recommended (1A)



The **Entire Sigmoid** should be resected, down to rectum (1c)



Anastomosis (1B) and Lap approach (1A) **preferred** if possible / safe



(though adoption rates low in acute setting)

3.9%

DISEASES OF THE COLON & RECTUM



Hall J et al. *Dis Colon Rectum* 2020;63(6):728-47

