

The American Society of Colon and Rectal Surgeons Clinical Practice Guidelines for the Management of Colonic Volvulus and Acute Colonic Pseudo-Obstruction

Karim Alavi, M.D., M.P.H.¹ • Vitaliy Poylin, M.D.² • Jennifer S. Davids, M.D.¹
 Sunil V. Patel, M.D.³ • Seth Felder, M.D.⁴ • Michael A. Valente, D.O.⁵
 Ian M. Paquette, M.D.⁶ • Daniel L. Feingold, M.D.⁷

Prepared on behalf of the Clinical Practice Guidelines Committee of the American Society of Colon and Rectal Surgeons

1 University of Massachusetts Medical School, Worcester, Massachusetts

2 Northwestern University, Chicago, Illinois

3 Queen's University, Kingston, Ontario, Canada

4 Moffitt Cancer Center, Tampa, Florida

5 Cleveland Clinic, Cleveland, Ohio

6 University of Cincinnati, Cincinnati, Ohio

7 Rutgers University, New Brunswick, New Jersey

The American Society of Colon and Rectal Surgeons (ASCRS) is dedicated to ensuring high-quality patient care by advancing the science, prevention, and management of disorders and diseases of the colon, rectum, and anus. The Clinical Practice Guidelines Committee is composed of society members who are chosen because they have demonstrated expertise in the specialty of colon and rectal surgery. This committee was created to lead international efforts in defining quality care for conditions related to the colon, rectum, and anus and develop clinical practice guidelines based on the best available evidence. Although not proscriptive, these guidelines provide information on which decisions can be made and do not dictate a specific form of treatment. These guidelines are intended for the use of all practitioners, health care workers, and patients who desire information about the management of the conditions addressed by the topics covered in these guidelines.

These guidelines should not be deemed inclusive of all proper methods of care nor exclusive of methods of care reasonably directed toward obtaining the same results. The ultimate judgment regarding the propriety of any specific procedure must be made by the physician considering all the circumstances presented by the individual patient.

STATEMENT OF THE PROBLEM

Large-bowel obstruction (LBO) in adults results from either mechanical or nonmechanical causes, and the 3 most common mechanical causes of LBO include obstructing colon or rectal cancer, diverticular stricture, and colonic volvulus.^{1,2} Colonic volvulus is the twisting of a redundant segment of colon on its mesentery that may lead to luminal occlusion in and proximal to the volvulized segment and compromise of colonic blood supply resulting in ischemia, gangrene, and potentially perforation.³⁻⁵ Colonic volvulus accounts for 10% to 15% of all large-bowel obstructions in the United States and western Europe, although its worldwide incidence is variable with a slightly higher rate in India, Africa, and the Middle East (the so-called “volvulus belt”).⁵ Although volvulus can occur in any redundant colonic segment, it most commonly involves the sigmoid (60%–75% of all cases) and cecum (25%–40% of all cases).⁶⁻⁸ Sigmoid volvulus preferentially affects older men in the United States and westernized countries, although younger men are more commonly affected in the volvulus belt.⁶ In the United States and westernized countries, sigmoid volvulus

Earn Continuing Education (CME) credit online at cme.lww.com. This activity has been approved for AMA PRA Category 1 credit.TM

Funding/Support: None reported.

Financial Disclosures: None reported.

Correspondence: Daniel L. Feingold, M.D., Professor and Chair, Section of Colorectal Surgery, Rutgers University, 125 Patterson St, New Brunswick, NJ 08901. E-mail: daniel.feingold@rutgers.edu.

Dis Colon Rectum 2021; 64: 1046–1057

DOI: 10.1097/DCR.0000000000002159

© The ASCRS 2021

primarily presents during the 6th to 8th decade of life, in institutionalized patients, and in patients with chronic constipation, neuropsychological impairment, or significant comorbidities.^{3,5,7,9} In contrast, cecal volvulus typically presents in younger patients and has a female predominance.³ The management of volvulus depends on its location and clinical presentation. Pillars of management include the assessment of colonic viability, relief of obstruction, and prevention of recurrence. Without operative intervention, recurrent volvulus rates are high, and each subsequent recurrence event risks ischemia and perforation.^{10–13}

Meanwhile, acute colonic pseudo-obstruction (ACPO), or Ogilvie syndrome, is a nonmechanical, functional cause of LBO thought to be a consequence of dysregulation of the autonomic impulses of the colonic enteric nervous system.^{14,15} Whereas ACPO presents as a large-bowel obstruction in the absence of a mechanical cause that can progress to ischemia and subsequent perforation,^{14,16–23} patients' specific clinical presentations vary according to the degree of colonic distension, whether or not the ileocecal valve is competent, and the overall condition of the patient. Most commonly, ACPO affects elderly patients or patients admitted to the hospital for unrelated reasons, including elective surgery, trauma, or the management of an acute medical condition. This practice guideline focuses on the evaluation and treatment of adult patients with sigmoid or cecal volvulus or ACPO.

METHODOLOGY

These guidelines were built on the ASCRS practice guidelines for colon volvulus and ACPO published in 2016.²⁴ A systematic search of MEDLINE, PubMed, Scopus, and the Cochrane Database of Systematic Reviews was performed from January 1, 2014 through January 19, 2021. Individual literature searches were conducted for each statement within the guideline and were restricted to English language and adult patients (Fig. 1). Search strategies were based on the concepts of volvulus, pseudo-obstruction, and the various relevant diagnostic procedures and surgical interventions related to these diagnoses using multiple subject headings, text words, and descriptors. The 1577 screened articles were evaluated for their level of evidence, favoring clinical trials, meta-analysis and systematic reviews, comparative studies, and large registry retrospective studies over single-institutional series, retrospective reviews, and observational studies. Additional references identified through embedded references and other resources as well as practice guidelines or consensus statements from relevant societies were also reviewed. One hundred twenty-five tabulated citations were evaluated for methodologic quality, the evidence base was examined, and a treatment guideline was formulated by the subcommittee for this guideline. The final grade of recommendation and level

of evidence for each statement were determined using the Grades of Recommendation, Assessment, Development, and Evaluation system (Table 1). When agreement was incomplete regarding the evidence base or treatment guideline, consensus from the committee chair, vice chair, and 2 assigned reviewers determined the outcome. Members of the ASCRS Clinical Practice Guidelines Committee worked in joint production of these guidelines from inception to final publication. Recommendations formulated by the subcommittee were reviewed by the entire Clinical Practice Guidelines Committee. The guideline was peer reviewed by *Diseases of the Colon & Rectum* and the final guideline was approved by the ASCRS Executive Council. In general, each ASCRS Clinical Practice Guideline is updated every 5 years. No funding was received for preparing this guideline and the authors have declared no competing interests related to this material. This guideline conforms to the Appraisal of Guidelines for Research and Evaluation (AGREE) checklist.

COLONIC VOLVULUS

- 1. Initial evaluation should include a focused history, physical examination, and basic laboratory assessment. Grade of recommendation: Strong recommendation based on low-quality evidence, 1C.**

Presenting symptoms of both sigmoid and cecal volvulus are often nonspecific and may include abdominal pain, bloating, or cramping, nausea, emesis, and obstipation.^{4,5,7,12,26} It may be difficult to obtain an accurate history in patients with neuropsychiatric disorders and patients residing in long-term care facilities who rely on others to relay key historical events. Physical examination typically reveals a distended and tympanic abdomen with varying degrees of tenderness. Digital rectal examination usually reveals an empty vault.^{4,5,7,12,26–28}

Although the duration of symptoms before presentation ranges from a few hours to several days, cecal volvulus tends to present more acutely, whereas sigmoid volvulus often has a more indolent presentation.^{4,11,27,29–31} Emergency presentation, with clinical signs of peritonitis or shock related to ischemia or perforation occurs in up to 25% and 35% of patients with sigmoid and cecal volvulus.^{12,28,30,32} Because patients with colonic volvulus frequently have comorbid conditions or may have electrolyte derangements or acute renal insufficiency secondary to emesis or dehydration, laboratory testing is often helpful during the initial evaluation of patients with suspected colonic volvulus. In general, the history and physical examination and radiological evaluations occur in parallel to facilitate care.

- 2. In hemodynamically stable patients, colonic volvulus is often initially evaluated with plain abdominal radiographs, whereas CT imaging may be used to confirm the diagnosis. Grade of recommendation: Strong recommendation based on low-quality evidence, 1C.**

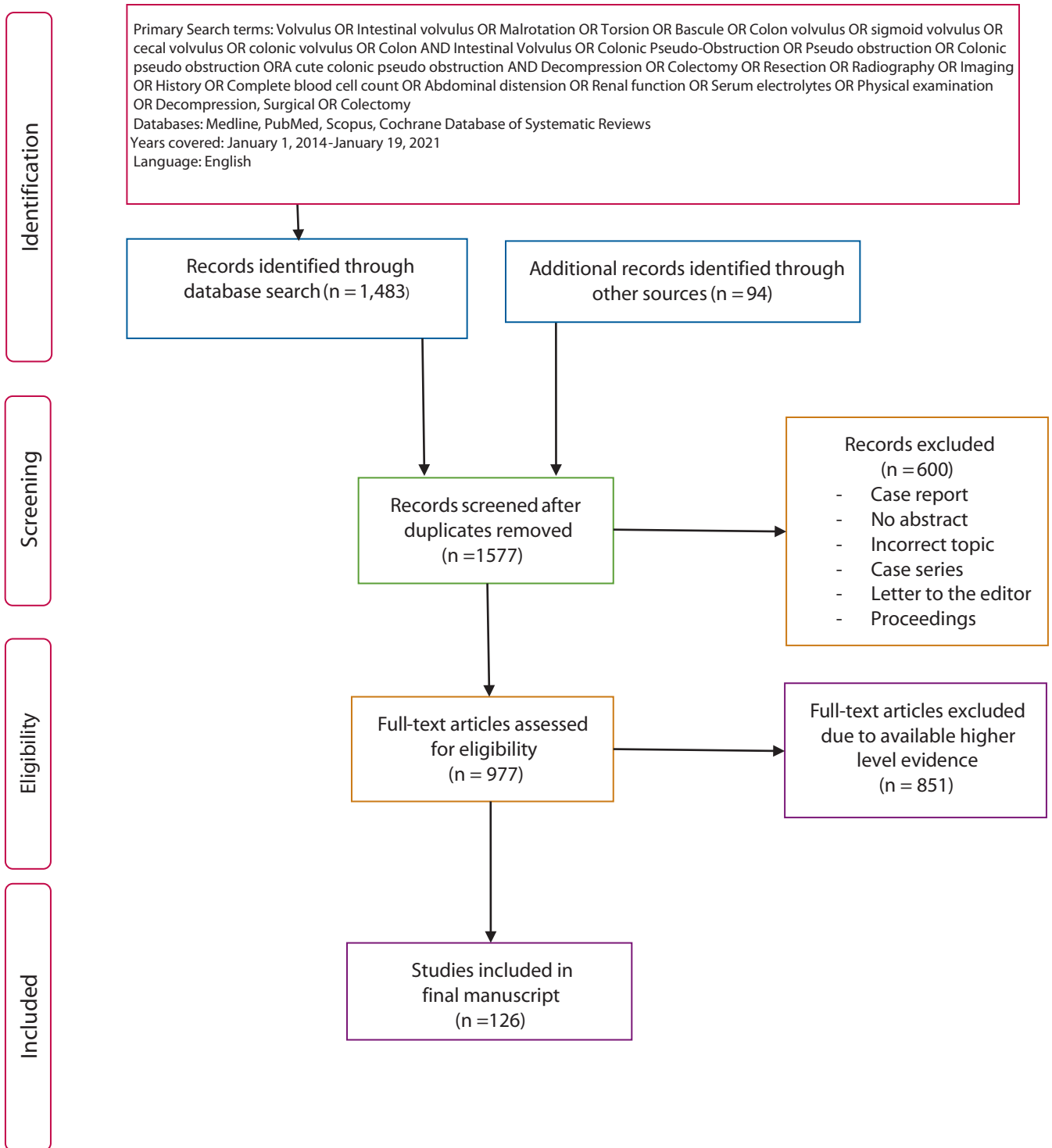


FIGURE 1. PRISMA literature search flow sheet.

Imaging early during suspected volvulus can confirm the diagnosis and expedite care. Plain abdominal radiographs are typically performed, because the initial diagnostic evaluation and radiographs often demonstrate a distended loop of colon that may resemble a coffee bean or bent inner tube projecting toward the upper abdomen

and, in patients with an incompetent ileocecal valve, may also show a distended small bowel with air-fluid levels.^{4,33-36} In a retrospective series of 103 cases of volvulus, Swenson and colleagues¹¹ demonstrated that abdominal radiographs were suggestive or diagnostic for cecal and sigmoid volvulus in 42% and 81% of patients. Lau et al,³³

TABLE 1. The GRADE System: grading recommendations

Grade	Description	Benefit versus risk and burdens	Methodologic quality of supporting evidence	Implications
1A	Strong recommendation, High-quality evidence	Benefits clearly outweigh risk and burdens or vice versa	RCTs without important limitations or overwhelming evidence from observational studies	Strong recommendation, can apply to most patients in most circumstances without reservation
1B	Strong recommendation, Moderate-quality evidence	Benefits clearly outweigh risk and burdens or vice versa	RCTs with important limitations (inconsistent results, methodologic flaws, indirect or imprecise) or exceptionally strong evidence from observational studies	Strong recommendation, can apply to most patients in most circumstances without reservation
1C	Strong recommendation, Low- or very-low quality evidence	Benefits clearly outweigh risk and burdens or vice versa	Observational studies or case series	Strong recommendation but may change when higher-quality evidence becomes available
2A	Weak recommendation, High-quality evidence	Benefits closely balanced with risks and burdens	RCTs without important limitations or overwhelming evidence from observational studies	Weak recommendation, best action may differ depending on circumstances or patients' or societal values
2B	Weak recommendations, Moderate-quality evidence	Benefits closely balanced with risks and burdens	RCTs with important limitations (inconsistent results, methodologic flaws, indirect or imprecise) or exceptionally strong evidence from observational studies	Weak recommendation, best action may differ depending on circumstances or patients' or societal values
2C	Weak recommendation, Low- or very-low quality evidence	Uncertainty in the estimates of benefits, risks and burden; benefits, risk and burden may be closely balanced	Observational studies or case series	Very weak recommendations; other alternatives may be equally reasonable

GRADE = Grades of Recommendation, Assessment, Development, and Evaluation; RCT = randomized controlled trial.

Adapted from Guyatt G, Guterman D, Baumann MH, et al. Grading strength of recommendations and quality of evidence in clinical guidelines: report from an American College of Chest Physicians Task Force. *Chest*. 2006;129:174–181.²⁵ Used with permission.

in a retrospective study of 40 patients, reported that plain abdominal radiographs were diagnostic of cecal and sigmoid volvulus in 26% and 66% patients. Plain abdominal radiographs may also reveal other associated findings such as pneumoperitoneum or pneumatosis, which can influence treatment.

In cases where clinical assessment and plain abdominal radiographs are insufficient to confirm the diagnosis of colon volvulus, CT imaging with or without rectal contrast should be considered. Despite a lack of randomized, controlled trials evaluating cross-sectional imaging in this setting, CT imaging is the preferred confirmatory diagnostic study for both cecal and sigmoid volvulus. Computed tomography is noninvasive, easily obtainable, accurate, and can identify coincidental pathology that may otherwise be missed with plain radiographs or fluoroscopic contrast studies.^{5,6,11,26,35,36} Other colon-related diagnoses that can mimic the presentation of volvulus, such as cecal bascule, obstruction secondary to neoplasm, or pseudo-obstruction, can also be diagnosed with CT.^{36–41} Computed tomography with multiplanar reconstruction can diagnose volvulus with near 100% sensitivity and a specificity >90%.⁶ In a retrospective review of 50 cases of sigmoid volvulus and 53 cases of cecal volvulus by Swenson et al,¹¹ CT without rectal contrast had an average positive diagnostic yield of 77%. Computed tomography may reveal a “whirl sign” representing the point of torsion in the mesentery around which bowel loops and mesenteric vessels are torsed.^{5,6,26} If the diagnosis remains in question despite

imaging, repeat imaging using rectal contrast may better define the anatomy and confirm the diagnosis.

In cases where the diagnosis remains elusive despite axial imaging, a water-soluble contrast enema may help confirm the diagnosis by demonstrating a smooth, tapered point of obstruction, known as a “bird’s beak,” at the level of the volvulus.^{4,11,27,33,34,37,38} Swenson et al¹¹ demonstrated that contrast enema was suggestive of or diagnostic for cecal and sigmoid volvulus in 44% and 78% of patients. Lau et al³³ found that the combination of plain abdominal radiographs and contrast enema images was diagnostic for cecal and sigmoid volvulus in 42% and 90% of patients. Older retrospective studies support using contrast enema in cases of suspected volvulus and show that the point of torsion could be identified in ≈70% of cases.^{27,37,38}

SIGMOID VOLVULUS

3. Patients without hemodynamic instability, peritonitis, or evidence of perforation should typically undergo lower endoscopy to assess sigmoid colon viability, detorse the anatomy, and decompress the colon. Grade of recommendation: Strong recommendation based on low-quality evidence, 1C.

In stable patients without colonic ischemia or perforation, the first-line therapy for sigmoid volvulus is endoscopic detorsion, which is effective in 60% to 95% of patients.^{7,12,28,29,39–43} Detorsion and assessment of the volvulized

segment for mucosal ischemia or gangrene may be performed using rigid proctoscopy or flexible sigmoidoscopy that can access more proximal transition points, as needed.^{7,28,39,44–46} Endoscopy may visualize the classic mucosal pinwheel at the point of obstruction before detorsion. Care should be taken when selecting patients for endoscopic detorsion; specifically, those presenting with signs and symptoms of bowel ischemia, perforation, or impending perforation should typically undergo operative intervention instead of endoscopic intervention.

After successful detorsion of the sigmoid colon, a decompression tube may be left in place to allow for continued colonic decompression and to facilitate preoperative mechanical bowel preparation, as needed.^{7,9,28,29,41,42,46–49} Patients with sigmoid volvulus who undergo successful endoscopic detorsion without subsequent intervention have a 43% to 75% recurrence rate.^{9,28,29,39,50,51} The high risk for recurrent volvulus and the potential morbidity and mortality associated with each recurrent episode, specifically in the frail, elderly population, support the recommendation for operative intervention during patients' index admission or soon thereafter.^{9,11,28,29,39,51,52}

4. Urgent sigmoid resection is indicated when endoscopic detorsion of the sigmoid colon fails and in cases of nonviable or perforated colon. Grade of recommendation: Strong recommendation based on low-quality evidence, 1C.

Patients who present with colonic ischemia or perforation, peritonitis, or septic shock or in whom endoscopic detorsion fails^{7,11,28,45,48,53–59} require urgent sigmoid resection. Resection is often aided by manual detorsion that restores the normal lay of the anatomy and facilitates mesenteric division.^{60,61} After the volvulized segment has been resected, the decision to perform a primary colorectal anastomosis, end colostomy, or defunctionalized colorectal anastomosis should be individualized after considering multiple factors including the patients' clinical status at the time of surgery, health of the remaining colon, and comorbidities.

When analyzing the evidence base, it is important to recognize that the studies evaluating different operative solutions for the management of sigmoid volvulus are mainly retrospective in nature and include an unquantifiable degree of patient selection bias. The Hartmann procedure, the most commonly performed operation for patients who have sigmoid volvulus with a nonviable colon and peritonitis, has an associated mortality rate of 5% to 7%.^{28,45} Meanwhile, resection with primary anastomosis has a leak rate of 4.7% and a mortality rate of 3.4%, according to a retrospective review of 1514 patients from the American College of Surgeons National Surgical Quality Improvement Program (ACS NSQIP) Database who underwent surgery between 2012 and 2015.⁶² Kuzu et al⁵⁴ retrospectively reviewed 106 consecutive sigmoid

volvulus cases managed with a sigmoid resection with end colostomy (n = 49) versus sigmoid resection with colorectal anastomosis without proximal diversion (n = 57). In this study, a Hartmann procedure was used more often in patients with a nonviable colon or peritonitis and was associated with increased postoperative complications and mortality (8% and 5%), whereas anastomotic leak occurred in 7% of patients who did not undergo diversion. End colostomy is often the most appropriate choice for higher-risk patients under the circumstances (eg, patients with higher ASA class, acidosis, sepsis, coagulopathy).^{3,39,53,54} High-level evidence comparing open versus minimally invasive approaches in emergency volvulus surgery is lacking, but available data suggest similar outcomes in selected patients.^{63,64}

5. Patients who undergo successful endoscopic detorsion should be considered for sigmoid colectomy during the same hospital admission to prevent recurrent volvulus. Grade of recommendation: Strong recommendation based on low-quality evidence, 1C.

Although endoscopic treatment of volvulus is successful in most patients, the rate of recurrent volvulus after detorsion is high (range, 43%–75%) and patients with recurrent volvulus are again at risk for bowel ischemia and morbidity.^{11,29,51,57} According to 2 single-institution retrospective reviews with 168 and 83 patients, patients managed with emergency surgery at the time of recurrent sigmoid volvulus had much higher mortality (13% and 62%) than patients who had elective surgery following their initial volvulus episode (3.3% and 32%).^{43,51} Yassaie et al⁵⁷ studied 31 patients with sigmoid volvulus who underwent successful endoscopic detorsion without further intervention and diagnosed recurrent sigmoid volvulus in 19 patients (61%) at a median of 31 days. Of these 19 patients, 7 underwent colectomy and 12 had repeat endoscopic detorsion alone. Of these 12 patients, 5 (42%) were diagnosed with a third episode of volvulus at a median interval of 5 months, and 3 (25%) required emergency sigmoid colectomy. Similarly, Swenson et al¹¹ demonstrated recurrence in 10 of 21 patients (48%) at a median of 106 days (range, 8–374 days) after nonoperative management of sigmoid volvulus, and Tan et al⁴⁸ documented recurrent sigmoid volvulus in 28 of 46 patients (61%) who were managed with endoscopic reduction alone.

A more recent single-center, longitudinal, cohort study evaluated 168 patients with sigmoid volvulus who had a total of 453 hospital admissions.⁵¹ In this cohort, a total of 438 nonoperative decompressions were attempted that were successful in 403 (92%) cases. Of 111 patients treated without surgery after their index episode, 87 (78%) had a recurrence; patients who had a recurrence experienced a median of 2 recurrences (range, 1–16 recurrences), and the median number of days to recurrence was 58.

Of the variety of elective and semielective operations that have been described for sigmoid volvulus, sigmoid colectomy with or without colorectal anastomosis is the most effective at preventing recurrent volvulus.^{7,11,28,29,39,57} Under these circumstances, removing the segment of the redundant colon reduces the risk of recurrence. Mobilization of the splenic flexure at the time of surgery is not typically required given the redundancy encountered. In patients with a sigmoid volvulus and viable, nonperforated bowel, sigmoid resection with primary anastomosis can result in low morbidity and mortality (12% and 0%).^{11,29,39,65} Stoma creation in the nonemergent setting is not usually necessary and should be individualized based on the operative findings and unique patient factors. In a study of 1813 patients with sigmoid volvulus using data from the ACS NSQIP database from 2012 to 2015, primary anastomosis was associated with a 5.3% anastomotic leak rate, a 3.6% mortality, and 36% overall morbidity at 30 days.⁶⁶ Although minimally invasive and open approaches have been described in the management of volvulus, surgeon and patient factors influence the selection of the operative plan. The redundancy and mobility of the colon and the associated mesentery usually allow for colectomy via a minilaparotomy.^{63,64,67,68} Finally, in patients with a history of volvulus in other segments of the colon or concurrent megacolon, subtotal colectomy should be considered because it may be more effective in preventing future volvulus than sigmoid colectomy alone.^{69,70}

6. Operations without resection including detorsion alone, sigmoidopexy, and mesosigmoidoplasty are inferior to sigmoid colectomy for the prevention of recurrent volvulus. Grade of recommendation: Weak recommendation based on low-quality evidence, 2C.

Operative detorsion alone, detorsion with fixation (sigmoidopexy), or tailoring of the sigmoid mesentery to broaden its base to prevent recurrent torsion (mesosigmoidoplasty) have been described as nonresectional treatments for sigmoid volvulus in patients with viable colon. Older retrospective studies of operative detorsion alone reported recurrence rates of 18% to 48% and mortality rates of 11% to 15%, all higher than sigmoid colectomy.^{28,39,50,60,71} Although small studies have reported successful sigmoidopexy and mesosigmoidoplasty, larger series report high recurrence rates of 16% to 21% after surgery without resection.^{28,39}

7. Endoscopic fixation of the sigmoid colon may be considered in selected patients in whom operative intervention presents a prohibitive risk. Grade of recommendation: Weak recommendation based on low-quality evidence, 2C.

Alternatives to sigmoid resection have been suggested for patients after nonoperative treatment of sigmoid volvulus who are frail or otherwise unfit for surgery. A number of

small case series have investigated the role of advanced endoscopic techniques as a less invasive means to prevent recurrent sigmoid volvulus.^{10,30,72,73} Fixation using percutaneous endoscopic colostomy (PEC) or T-fasteners with or without laparoscopic assistance can be used to fix the sigmoid colon to the anterior abdominal wall preventing recurrent volvulus.^{10,29,74–78} Reported techniques vary in terms of the number of fixation points used (2–10) and whether PEC tubes are removed after a specified time interval.²⁹ Studies evaluating these techniques usually include patients deemed ineligible for conventional surgery due to significant comorbidities and report high rates of successful endoscopic fixation (66%–100%). However, major complications (eg, peritonitis, tube migration, or death) have been reported in up to 25% of patients and recurrence rates range from 0% to 17% within 12 months. Recognizing the high-risk population included in these studies, the mortality attributed to nonvolvulus causes in these patient cohorts was higher than the mortality due to the procedure itself. Based on the available small case series, endoscopic fixation may be considered for the treatment of sigmoid volvulus in patients where operative intervention carries a prohibitive risk.

CECAL VOLVULUS

8. Attempts at endoscopic reduction of cecal volvulus are generally not recommended. Grade of recommendation: Strong recommendation based on low-quality evidence, 1C.

Unlike sigmoid volvulus, studies do not support endoscopy as an initial approach to patients with cecal volvulus. Aggregate data from multiple small, retrospective studies from 1978 to 2012 included a total of 51 patients in whom endoscopic reduction was attempted reported successful detorsion in only 7 patients (14%).^{11,30,41,79,80} Given the low probability of success and the potential for procedure-related perforation, attempts at endoscopic reduction of cecal volvulus delay operative intervention and are not recommended.^{27,40,81,82}

9. Segmental resection is the preferred treatment for patients with cecal volvulus. Grade of recommendation: Strong recommendation based on low-quality evidence, 1C.

Nonviable or gangrenous cecum is present in 18% to 44% of patients with cecal volvulus and is associated with a significant mortality rate.^{7,8,27,31,33,83–85} Comparisons of surgical outcomes in the setting of cecal volvulus with viable and nonviable bowel are mainly from decades-old retrospective studies.^{7,27,84,85} One of the largest historical series of cecal volvulus is a 1990 pooled retrospective review of 561 cases published between 1959 and 1989 in which 20% of patients had nonviable bowel. Resection in this pooled

review was performed primarily for volvulus cases complicated by a gangrenous cecum and the overall morbidity, mortality, and recurrence rates for the 140 patients who underwent resection were 29%, 22%, and 0%.³¹ In a retrospective, single-institution study that included 35 patients with cecal volvulus who underwent resection and anastomosis, the 15 patients who had gangrenous bowel had greater than twice the mortality rate of those with viable bowel (33% versus 12%), and no recurrences were observed following resection and anastomosis.⁷

A more recent retrospective study utilizing ACS NSQIP data evaluated risk factors for complications following segmental colectomy and primary anastomosis for cecal volvulus in 661 patients.⁶² In this study, although overall morbidity was 45.7%, the anastomotic leak rate was 4.1% and the mortality rate was 3.3%. Adjusted analysis demonstrated that statistically significant predictors of mortality included age, male sex, current smoking, and ASA ≥ 4 , whereas predictors of any complication included septic shock, wound class ≥ 3 , and ASA ≥ 4 . On multivariable analysis, the only predictor of anastomotic leak was wound class ≥ 3 . Whereas the nature of the ACS NSQIP database precluded determination of bowel viability, one may extrapolate that a higher ASA, contaminated or dirty wounds, and septic shock were likely more common in patients with nonviable bowel.

Collectively, the data support that overall mortality after colectomy with anastomosis for cecal volvulus has decreased over time and that the leak rate is low.^{62,81,85} Laparoscopic resection may be a reasonable alternative to laparotomy, although the redundant anatomy in these cases can usually be addressed via minilaparotomy.⁶² Although the data regarding resection with end stoma creation in the setting of cecal volvulus are limited, this option should be considered in higher-risk patients and in patients with nonviable bowel. Finally, the treatment recommendations for patients with symptomatic cecal bascule are similar to those discussed for patients with the more common form of organoaxial cecal volvulus.⁸⁶

10. For cecal volvulus with viable bowel, the use of non-resectional operative procedures should be limited to patients who are considered unfit for resection. Grade of recommendation: Weak recommendation based on low-quality evidence, 2C.

In patients with cecal volvulus with viable bowel, alternatives to resection include manual detorsion alone or detorsion with fixation to the abdominal wall either by suture (cecopexy) or cecostomy. For each potential intervention, the risks of postoperative morbidity and mortality should be weighed against the risk of recurrence. Rabinovici et al³¹ compared surgical outcomes of 561 pooled patients with cecal volvulus from case series published between 1959 and 1989 and found higher rates of morbidity and mortality with resection than with cecopexy, 29% and 22%

versus 15% and 10%; however, cecopexy was associated with a 13% recurrence rate, whereas the resection group experienced no recurrences. The authors recommended against cecostomy, which was associated with the highest morbidity, mortality, and recurrence rates (52%, 32%, and 14%). In addition, single-center, retrospective studies report low mortality rates for resection in cases with viable bowel, but increased morbidity, mortality, and recurrence rates following nonresection approaches.^{7,8,11,27,30,32} With more than one possible operative intervention available for cecal volvulus with viable bowel, the decision regarding the most appropriate intervention should be individualized with consideration given to the condition of the patient and the bowel.⁸² In general, the use of a nonresection approach should be limited to clinical circumstances where a patient is unfit for a resection of the volvulized segment.

ACUTE COLONIC PSEUDO-OBSTRUCTION

11. Initial evaluation should include a focused history and physical examination, baseline laboratory values, and diagnostic imaging. Grade of recommendation: Strong recommendation based on low-quality evidence, 1C.

Acute colonic pseudo-obstruction most often affects older, hospitalized, or institutionalized patients who have comorbid conditions, have an infection, or are recovering from surgery or trauma.^{20,22,40,72,87,88} Typical signs and symptoms include abdominal pain, nausea, vomiting, abdominal distension, altered bowel function, and dilation of the ascending and transverse colon without evidence of mechanical obstruction on imaging.^{17,22,73} Given that patients with suspected ACPO frequently have comorbid conditions and may have electrolyte derangements or acute renal insufficiency, routine laboratory testing, such as a basic metabolic panel, should be included during the initial evaluation.^{21,89-94} Because the management of mechanical LBO differs from ACPO, excluding a mechanical LBO and other conditions that can contribute to colon dilation is critical. Computed tomography or water-soluble contrast enema can reliably distinguish ACPO from a mechanical large-bowel obstruction.⁹⁵⁻⁹⁸ Unless there is a high suspicion for a distal obstruction, endoscopy is not typically recommended for diagnostic purposes given the associated risk of perforation in the setting of colon dilation.^{16,40,99}

12. Initial treatment of ACPO is supportive and includes eliminating or correcting conditions that predispose patients to ACPO or prolong its course. Grade of recommendation: Strong recommendation based on low-quality evidence, 1C.

In the absence of fever, leukocytosis, abdominal tenderness, free air, or cecal diameter >12 cm, first-line therapy

for patients with ACPO includes correction of serum electrolyte abnormalities, fluid resuscitation, avoidance or minimization of narcotics, avoidance of anticholinergic medications (eg, oxybutynin or benztropine), and identification and treatment of any concomitant infection. The management of ACPO includes ambulation, bowel rest, alternating positioning (knee-chest or prone) to promote GI motility, and decompression with nasogastric and/or rectal tubes.^{17,22,40,100–102} Under these circumstances, oral osmotic and stimulant laxatives should be avoided because they may worsen colon dilation and produce more gas in an already dilated colon.^{17,22} Serial physical examinations and daily abdominal radiographs facilitate continuous reassessment to determine if patients with ACPO are responding favorably or worsening. Signs of ischemia or perforation, such as increased pain, fever, abdominal tenderness, or leukocytosis, should prompt urgent surgical evaluation. In a literature review including 400 pooled patients with ACPO, Vanek et al²⁰ demonstrated that ischemia or perforation was more likely with increasing cecal diameter (0%, 7%, and 23% risk with cecal diameters of <12 cm, 12–14 cm, and >14 cm). Although cutoff values for colonic distension and the associated risk of ischemia or perforation can be arbitrary, the rate of change in colon diameter on serial radiographs may represent a more important objective measure of response to therapy and risk of complications.

In the largest study published to date assessing ACPO treatment outcomes, Ross et al¹⁰³ included 106,784 cases from the National Inpatient Sample between 1998 to 2011, 91% of whom were managed medically. Medical complications and mortality were significantly less in the group managed medically (complications 44%, mortality 7.3%) than in those eventually requiring colonoscopy (complications 64%, mortality 9%), surgery (complications 60%, mortality 12.3%) or in those who required both colonoscopy and surgery (complications 74.6%, mortality 14.8%). Conclusions from these findings are limited by the lack of granularity of the data set, specifically as it relates to the use of medications such as neostigmine and the lack of clinical examination details.

When serial examinations and abdominal radiographs do not suggest colon ischemia, perforation, or impending perforation, a nonoperative approach should be continued with the expectation that it will lead to resolution of ACPO in 70% to 90% of patients.^{20,40,100–104} The decision to continue medical management or to escalate treatment is multifactorial and often individualized.

13. Pharmacologic treatment with neostigmine is indicated when ACPO does not resolve with supportive therapy. Grade of recommendation: Strong recommendation based on moderate-quality evidence, 1B.

In the setting of ongoing ACPO and in the absence of signs of mechanical obstruction or perforation, escalating

nonoperative treatment with a cholinesterase inhibitor is usually appropriate. Although not specifically approved by the US Food and Drug Administration for the treatment of ACPO, neostigmine has proven safe and effective for this indication.¹⁰⁵ Neostigmine is typically administered intravenously in bolus doses of 2 to 2.5 mg, although studies have noted success with continuous infusion, particularly in patients refractory to bolus dosing.^{72,88,106,107}

Placebo-controlled, randomized trials of intravenous neostigmine have demonstrated resolution of colon dilation up to 90% of cases.^{72,88,106} In the landmark randomized, blinded, placebo-controlled study by Ponc et al,⁸⁸ 10 of 11 patients (91%) with ACPO who received 2 mg of neostigmine intravenously experienced a clinical response at a median interval of 4 minutes (range, 3–30 minutes). Although the authors considered neostigmine to have failed in 3 of the 11 cases (27%), 1 of the 3 initial nonresponders subsequently responded to a second dose of neostigmine, whereas the other 2 were managed with colonoscopic decompression. Of the 10 patients in whom placebo initially failed, 7 had a sustained clinical and radiographic response after ultimately receiving neostigmine. In a similarly designed trial by Amaro et al,¹⁰⁶ of 18 patients treated with 2-mg bolus neostigmine, 17 (94%) had an immediate clinical response and 16 patients (89%) had sustained colonic decompression.

A meta-analysis including randomized and non-randomized trials of neostigmine reported that a single intravenous dose of 2 to 5 mg was successful in 60% to 94% of patients with ACPO, had a recurrence rate of 0% to 31%, and had an overall long-term response of 69% to 100%.⁷² For initial nonresponders or partial responders to neostigmine, a second neostigmine dose has proven effective in 40% to 100% of patients.^{22,23,40,108,109} Electrolyte abnormalities and recent antimotility agent use (eg, postoperative narcotics or anti-Parkinson medications) have been implicated as risk factors for not responding to neostigmine.^{101,110}

In terms of alternatives to bolus intravenous neostigmine administration, retrospective reviews and 1 randomized trial demonstrated that continuous infusion delivery had safety and efficacy similar to bolus dosing, but was associated with an increased number of bradycardic events.^{106,111,112} Acute colonic pseudo-obstruction has also been treated with subcutaneous neostigmine.¹¹³ In a multicenter, retrospective study of 182 patients with ileus, ACPO, or refractory constipation 0.25 to 1 mg of subcutaneous neostigmine resulted in a bowel movement within a median 29 hours.¹¹⁴ In addition, case reports support using subcutaneous methylnaltrexone in neostigmine-refractory patients with ACPO exposed to opioids.^{115,116}

Adverse events associated with the use of neostigmine for ACPO are attributed to excess acetylcholine and include transient abdominal pain (50%–73%), sialorrhea (23%–38%), vomiting (10%–20%), and bradycardia

(5%–9%).⁷² Neostigmine should be administered in an appropriate setting with cardiopulmonary monitoring that allows for immediate support and treatment in the event of bronchospasm or bradycardia (eg, having available glycopyrrolate or atropine).^{17,22,88,117}

14. Endoscopic colonic decompression should be considered in patients with ACPO in whom neostigmine therapy is contraindicated or ineffective. Grade of recommendation: Strong recommendation based on moderate-quality evidence, 1B.

In patients with ACPO who have not been treated with neostigmine, endoscopic decompression of the colon is initially successful in 61% to 95% of cases, and 70% to 90% of patients experience sustained decompression.^{20,23,40,87,100,118} Colonoscopic decompression has been proposed as a better first-line option than neostigmine, although there are limited data directly comparing these therapies.^{119,120} In a retrospective, propensity-matched study evaluating colonoscopic decompression combined with supportive and/or pharmacologic therapy (n = 83) compared with a similar cohort that did not undergo colonoscopic decompression (n = 61), the combined approach resulted in a higher rate of ACPO resolution as determined by radiographs (48% versus 20%, $p < 0.001$).¹²¹

To adequately treat ACPO, more than one endoscopic decompression procedure and/or endoscopic placement of a decompression tube is often required. In a study of 50 patients with ACPO, 41 (82%) had 1 colonoscopic decompression with clinical success in 39 (95%), and 9 (18%) required multiple (2–4) procedures with clinical success in 5 (56%).⁸⁷ In the 8 patients (16%) in whom a decompression tube was not placed, clinical success was achieved in only 2 (25%). The overall clinical success of colonoscopic decompression was 88% (44 of 50), similar to the 82% success rate for the 125 patients who underwent colonoscopy in a pooled literature review by Vanek and Al-Salti.²⁰ Although decompression tube placement has not been studied in a randomized trial, the available data support leaving a decompression tube after endoscopic decompression. Data detailing the caliber of decompression tubes used and the extent of tube insertion within the colon are lacking.

Colonoscopy in ACPO has a perforation rate of 1% to 3%.^{22,23,40,100,122} A large administrative database study reported female sex, chronic obstructive pulmonary disease, and metastatic cancer as independent risk factors for endoscopic decompression failure.¹⁰³ In patients with ACPO in whom supportive, pharmacologic, and standard endoscopic therapies fail, and who have no evidence of colon perforation or ischemia, PEC may be considered before proceeding with surgical therapy.^{123,124}

15. Operative treatment is recommended for ACPO complicated by colon ischemia or perforation or ACPO refractory to pharmacologic and endoscopic therapies.

Grade of recommendation: Strong recommendation based on low-quality evidence, 1C.

Persistent colon dilation refractory to nonoperative measures occurs in about 10% of patients.^{20,87,88} Colon ischemia or perforation occurs in 3% to 10% of patients with ACPO and is more common in patients with cecal diameter >12 cm and/or duration of dilation >6 days.^{20,23,125} Although larger cecal diameter is associated with a higher risk of perforation, the duration of distension and the rate of distension are important factors that contribute to perforation even in cases with less extreme degrees of dilation.^{2,17}

The effectiveness of nonoperative, pharmacologic, and endoscopic therapy for ACPO has reduced the need for surgery to cases complicated by colon ischemia or perforation or dilation otherwise refractory to nonoperative therapies.^{17,22,40,87,117} Ross et al¹⁰³ reported on 106,784 ACPO cases from the National Inpatient Sample and demonstrated that patients in whom medical management and colonoscopic decompression failed and subsequently required operative intervention had double the rate of complications compared with those patients managed medically.

A literature review including 400 pooled patients with ACPO from the “preneostigmine era” reported that the 179 patients who underwent operative intervention had an overall mortality rate of 30%.²⁰ Of these patients, 129 (72%) received some form of ostomy, 25 (14%) had a resection, and 25 (14%) had a variety of other operations performed. Of the 129 patients with stoma who underwent tube cecostomy (n = 34), cecostomy (n = 61), or ileostomy or colostomy (n = 34), 100%, 95%, and 73%, experienced successful decompression with a mortality rate of 15%, 21%, and 41%.²⁰ The perioperative mortality rates with viable (n = 125), ischemic (n = 18), and perforated (n = 36) bowel were 26%, 44%, and 36%, whereas the mortality rates for patients treated with supportive therapy alone (n = 120) and patients treated endoscopically (n = 101) were 14% and 13%. Risk factors for death in this study included advanced age, cecal diameter >14 cm, prolonged period (≥ 4 days) of colonic distension, and the requirement for operative intervention.²⁰ Patients with ACPO complicated by colon ischemia or perforation or with ACPO refractory to pharmacologic and endoscopic therapies most commonly undergo surgery with stoma creation with or without resection.^{117,126}

REFERENCES

1. Lopez-Kostner F, Hool GR, Lavery IC. Management and causes of acute large-bowel obstruction. *Surg Clin North Am.* 1997;77:1265–1290.
2. Yeo HL, Lee SW. Colorectal emergencies: review and controversies in the management of large bowel obstruction. *J Gastrointest Surg.* 2013;17:2007–2012.

3. Halabi WJ, Jafari MD, Kang CY, et al. Colonic volvulus in the United States: trends, outcomes, and predictors of mortality. *Ann Surg.* 2014;259:293–301.
4. Raveenthiran V, Madiba TE, Atamanalp SS, De U. Volvulus of the sigmoid colon. *Colorectal Dis.* 2010;12(7 online):e1–17.
5. Bauman ZM, Evans CH. Volvulus. *Surg Clin North Am.* 2018;98:973–993.
6. Perrot L, Fohlen A, Alves A, Lubrano J. Management of the colonic volvulus in 2016. *J Visc Surg.* 2016;153:183–192.
7. Ballantyne GH, Brandner MD, Beart RW Jr, Ilstrup DM. Volvulus of the colon. Incidence and mortality. *Ann Surg.* 1985;202:83–92.
8. Hiltunen KM, Syrjä H, Matikainen M. Colonic volvulus. Diagnosis and results of treatment in 82 patients. *Eur J Surg.* 1992;158:607–611.
9. Ballantyne GH. Review of sigmoid volvulus: history and results of treatment. *Dis Colon Rectum.* 1982;25:494–501.
10. Baraza W, Brown S, McAlindon M, Hurlstone P. Percutaneous endoscopic sigmoidopexy: a cost-effective means of treating sigmoid volvulus in Sub-Saharan Africa? *East Afr Med J.* 2007;84:1–2.
11. Swenson BR, Kwaan MR, Burkart NE, et al. Colonic volvulus: presentation and management in metropolitan Minnesota, United States. *Dis Colon Rectum.* 2012;55:444–449.
12. Grossmann EM, Longo WE, Stratton MD, Virgo KS, Johnson FE. Sigmoid volvulus in Department of Veterans Affairs Medical Centers. *Dis Colon Rectum.* 2000;43:414–418.
13. Larkin JO, Thekiso TB, Waldron R, Barry K, Eustace PW. Recurrent sigmoid volvulus - early resection may obviate later emergency surgery and reduce morbidity and mortality. *Ann R Coll Surg Engl.* 2009;91:205–209.
14. Naveed M, Jamil LH, Fujii-Lau LL, et al. American Society for Gastrointestinal Endoscopy guideline on the role of endoscopy in the management of acute colonic pseudo-obstruction and colonic volvulus. *Gastrointest Endosc.* 2020;91:228–235.
15. Coulie B, Camilleri M. Intestinal pseudo-obstruction. *Annu Rev Med.* 1999;50:37–55.
16. Chudzinski AP, Thompson EV, Ayscue JM. Acute colonic pseudo-obstruction. *Clin Colon Rectal Surg.* 2015;28:112–117.
17. De Giorgio R, Knowles CH. Acute colonic pseudo-obstruction. *Br J Surg.* 2009;96:229–239.
18. De Giorgio R, Barbara G, Stanghellini V, et al. Review article: the pharmacological treatment of acute colonic pseudo-obstruction. *Aliment Pharmacol Ther.* 2001;15:1717–1727.
19. Vanek P, Falt P, Urban O. Percutaneous endoscopic cecostomy in the treatment of recurrent colonic pseudo-obstruction a case report of the first procedure in the Czech Republic. *Rozhledy v chirurgii: mesicnik Ceskoslovenske chirurgicke spolecnosti* 2019;98:375–378.
20. Vanek VW, Al-Salti M. Acute pseudo-obstruction of the colon (Ogilvie's syndrome). An analysis of 400 cases. *Dis Colon Rectum.* 1986;29:203–210.
21. Haj M, Haj M, Rockey DC. Ogilvie's syndrome: management and outcomes. *Medicine (Baltimore).* 2018;97:e11187.
22. Saunders MD. Acute colonic pseudo-obstruction. *Gastrointest Endosc Clin N Am.* 2007;17:341–360.
23. Saunders MD, Kimmey MB. Systematic review: acute colonic pseudo-obstruction. *Aliment Pharmacol Ther.* 2005;22:917–925.
24. Vogel JD, Feingold DL, Stewart DB, et al. Clinical Practice Guidelines for Colon Volvulus and Acute Colonic Pseudo-Obstruction. *Dis Colon Rectum.* 2016;59:589–600.
25. Guyatt G, Guterme D, Baumann MH, et al. Grading strength of recommendations and quality of evidence in clinical guidelines: report from an American College of Chest Physicians Task Force. *Chest.* 2006;129:174–181.
26. Kapadia MR. Volvulus of the small bowel and colon. *Clin Colon Rectal Surg.* 2017;30:40–45.
27. O'Mara CS, Wilson TH Jr, Stonesifer GL, Stonesifer GL, Cameron JL. Cecal volvulus: analysis of 50 patients with long-term follow-up. *Ann Surg.* 1979;189:724–731.
28. Atamanalp SS. Treatment of sigmoid volvulus: a single-center experience of 952 patients over 46.5 years. *Tech Coloproctol.* 2013;17:561–569.
29. Bruzzi M, Lefèvre JH, Desaint B, et al. Management of acute sigmoid volvulus: short- and long-term results. *Colorectal Dis.* 2015;17:922–928.
30. Friedman JD, Odland MD, Bubrick MP. Experience with colonic volvulus. *Dis Colon Rectum.* 1989;32:409–416.
31. Rabinovici R, Simansky DA, Kaplan O, Mavor E, Manny J. Cecal volvulus. *Dis Colon Rectum.* 1990;33:765–769.
32. Anderson JR, Welch GH. Acute volvulus of the right colon: an analysis of 69 patients. *World J Surg.* 1986;10:336–342.
33. Lau KC, Miller BJ, Schache DJ, Cohen JR. A study of large-bowel volvulus in urban Australia. *Can J Surg.* 2006;49:203–207.
34. Burrell HC, Baker DM, Wardrop P, Evans AJ. Significant plain film findings in sigmoid volvulus. *Clin Radiol.* 1994;49:317–319.
35. Levsky JM, Den EI, DuBrow RA, Wolf EL, Rozenblit AM. CT findings of sigmoid volvulus. *AJR Am J Roentgenol.* 2010;194:136–143.
36. Rosenblat JM, Rozenblit AM, Wolf EL, DuBrow RA, Den EI, Levsky JM. Findings of cecal volvulus at CT. *Radiology.* 2010;256:169–175.
37. Agrez M, Cameron D. Radiology of sigmoid volvulus. *Dis Colon Rectum.* 1981;24:510–514.
38. Ericksen AS, Krasna MJ, Mast BA, Noshier JL, Brolin RE. Use of gastrointestinal contrast studies in obstruction of the small and large bowel. *Dis Colon Rectum.* 1990;33:56–64.
39. Oren D, Atamanalp SS, Aydinli B, et al. An algorithm for the management of sigmoid colon volvulus and the safety of primary resection: experience with 827 cases. *Dis Colon Rectum.* 2007;50:489–497.
40. ASGE Standards of Practice Committee; Harrison ME, Anderson MA, Appalaneni V, et al. The role of endoscopy in the management of patients with known and suspected colonic obstruction and pseudo-obstruction. *Gastrointest Endosc.* 2010;71:669–679.
41. Renzulli P, Maurer CA, Netzer P, Büchler MW. Preoperative colonoscopic derotation is beneficial in acute colonic volvulus. *Dig Surg.* 2002;19:223–229.
42. Bruusgaard C. Volvulus of the sigmoid colon and its treatment. *Surgery.* 1947;22:466–478.
43. Quénehervé L, Dagouat C, Le Rhun M, et al. Outcomes of first-line endoscopic management for patients with sigmoid volvulus. *Dig Liver Dis.* 2019;51:386–390.
44. Ghazi A, Shinya H, Wolfe WI. Treatment of volvulus of the colon by colonoscopy. *Ann Surg.* 1976;183:263–265.
45. Fagan PV, Stanfield B, Nur T, Henderson N, El-Haddawi F, Kyle S. Management of acute sigmoid volvulus in a provincial centre—a 20-year experience. *N Z Med J.* 2019;132:38–43.
46. Turan M, Sen M, Karadayi K, et al. Our sigmoid colon volvulus experience and benefits of colonoscope in detortion process. *Rev Esp Enferm Dig.* 2004;96:32–35.

47. Dülger M, Cantürk NZ, Utkan NZ, Gonullu NN. Management of sigmoid colon volvulus. *Hepatogastroenterology*. 2000;47:1280–1283.
48. Tan KK, Chong CS, Sim R. Management of acute sigmoid volvulus: an institution's experience over 9 years. *World J Surg*. 2010;34:1943–1948.
49. Welch GH, Anderson JR. Acute volvulus of the sigmoid colon. *World J Surg*. 1987;11:258–262.
50. Ifversen AK, Kjaer DW. More patients should undergo surgery after sigmoid volvulus. *World J Gastroenterol*. 2014;20:18384–18389.
51. Johansson N, Rosemar A, Angenete E. Risk of recurrence of sigmoid volvulus: a single-centre cohort study. *Colorectal Dis*. 2018;20:529–535.
52. Tsai MS, Lin MT, Chang KJ, Wang SM, Lee PH. Optimal interval from decompression to semi-elective operation in sigmoid volvulus. *Hepatogastroenterology*. 2006;53:354–356.
53. Bhatnagar BN, Sharma CL, Gautam A, Kakar A, Reddy DC. Gangrenous sigmoid volvulus: a clinical study of 76 patients. *Int J Colorectal Dis*. 2004;19:134–142.
54. Kuzu MA, Aşlar AK, Soran A, Polat A, Topcu O, Hengirmen S. Emergent resection for acute sigmoid volvulus: results of 106 consecutive cases. *Dis Colon Rectum*. 2002;45:1085–1090.
55. Akcan A, Akyıldız H, Artis T, Yılmaz N, Sozuer E. Feasibility of single-stage resection and primary anastomosis in patients with acute noncomplicated sigmoid volvulus. *Am J Surg*. 2007;193:421–426.
56. Coban S, Yılmaz M, Terzi A, et al. Resection and primary anastomosis with or without modified blow-hole colostomy for sigmoid volvulus. *World J Gastroenterol*. 2008;14:5590–5593.
57. Yassaie O, Thompson-Fawcett M, Rossaak J. Management of sigmoid volvulus: is early surgery justifiable? *ANZ J Surg*. 2013;83:74–78.
58. Mulugeta GA, Awlachev S. Retrospective study on pattern and outcome of management of sigmoid volvulus at district hospital in Ethiopia. *BMC Surg*. 2019;19:107.
59. Heo S, Kim HJ, Oh BJ, et al. Sigmoid volvulus: identifying patients requiring emergency surgery with the dark torsion knot sign. *Eur Radiol*. 2019;29:5723–5730.
60. Madiba TE, Thomson SR. The management of sigmoid volvulus. *J R Coll Surg Edinb*. 2000;45:74–80.
61. Mnguni MN, Islam J, Manzini V, et al. How far has the pendulum swung in the surgical management of sigmoid volvulus? Experience from the KwaZulu-Natal Teaching Hospitals and review of the literature. *Colorectal Dis*. 2012;14:1531–1537.
62. Althans AR, Aiello A, Steele SR, Bhama AR. Colectomy for caecal and sigmoid volvulus: a national analysis of outcomes and risk factors for postoperative complications. *Colorectal Dis*. 2019;21:1445–1452.
63. Basato S, Lin Sun Fui S, Pautrat K, Tresallet C, Pocard M. Comparison of two surgical techniques for resection of uncomplicated sigmoid volvulus: laparoscopy or open surgical approach? *J Visc Surg*. 2014;151:431–434.
64. Cartwright-Terry T, Phillips S, Greenslade GL, Dixon AR. Laparoscopy in the management of closed loop sigmoid volvulus. *Colorectal Dis*. 2008;10:370–372.
65. Kasten KR, Marcello PW, Roberts PL, et al. What are the results of colonic volvulus surgery? *Dis Colon Rectum*. 2015;58:502–507.
66. Dolejs SC, Guzman MJ, Fajardo AD, Holcomb BK, Robb BW, Waters JA. Contemporary management of sigmoid volvulus. *J Gastrointest Surg*. 2018;22:1404–1411.
67. Choi BJ, Jeong WJ, Kim SJ, Lee SC. Single-port laparoscopic surgery for sigmoid volvulus. *World J Gastroenterol*. 2015;21:2381–2386.
68. Seow-En I, Seow-Choen F. Sigmoid volvulus treated by mini-incision. *Tech Coloproctol*. 2014;18:1169–1171.
69. Chung YF, Eu KW, Nyam DC, Leong AF, Ho YH, Seow-Choen F. Minimizing recurrence after sigmoid volvulus. *Br J Surg*. 1999;86:231–233.
70. Morrissey TB, Deitch EA. Recurrence of sigmoid volvulus after surgical intervention. *Am Surg*. 1994;60:329–331.
71. Traoré D, Sanogo ZZ, Bengaly B, et al. Acute sigmoid volvulus: results of surgical treatment in the teaching hospitals of Bamako. *J Visc Surg*. 2014;151:97–101.
72. Valle RG, Godoy FL. Neostigmine for acute colonic pseudo-obstruction: a meta-analysis. *Ann Med Surg (Lond)*. 2014;3:60–64.
73. Norwood MG, Lykostratis H, Garcea G, Berry DP. Acute colonic pseudo-obstruction following major orthopaedic surgery. *Colorectal Dis*. 2005;7:496–499.
74. Daniels IR, Lamparelli MJ, Chave H, Simson JN. Recurrent sigmoid volvulus treated by percutaneous endoscopic colostomy. *Br J Surg*. 2000;87:1419.
75. Gordon-Weeks AN, Lorenzi B, Lim J, Cristaldi M. Laparoscopic-assisted endoscopic sigmoidopexy: a new surgical option for sigmoid volvulus. *Dis Colon Rectum*. 2011;54:645–647.
76. Khan MA, Ullah S, Beckly D, Oppong FC. Percutaneous endoscopic colostomy (PEC): an effective alternative in high risk patients with recurrent sigmoid volvulus. *J Coll Physicians Surg Pak*. 2013;23:806–808.
77. Pinedo G, Kirberg A. Percutaneous endoscopic sigmoidopexy in sigmoid volvulus with T-fasteners: report of two cases. *Dis Colon Rectum*. 2001;44:1867–1869.
78. Toebosch S, Tudyka V, Masclée A, Koek G. Treatment of recurrent sigmoid volvulus in Parkinson's disease by percutaneous endoscopic colostomy. *World J Gastroenterol*. 2012;18:5812–5815.
79. Theuer C, Cheadle WG. Volvulus of the colon. *Am Surg*. 1991;57:145–150.
80. Suzuki H, Yamamura T, Fujishiro M. Endoscopic detorsion using single-balloon endoscopy for cecal volvulus. *Dig Endosc*. 2020;32:149.
81. Madiba TE, Thomson SR. The management of cecal volvulus. *Dis Colon Rectum*. 2002;45:264–267.
82. Consorti ET, Liu TH. Diagnosis and treatment of caecal volvulus. *Postgrad Med J*. 2005;81:772–776.
83. Tejler G, Jiborn H. Volvulus of the cecum. Report of 26 cases and review of the literature. *Dis Colon Rectum*. 1988;31:445–449.
84. Anderson MJ Sr, Okike N, Spencer RJ. The colonoscope in cecal volvulus: report of three cases. *Dis Colon Rectum*. 1978;21:71–74.
85. Burke JB, Ballantyne GH. Cecal volvulus. Low mortality at a city hospital. *Dis Colon Rectum*. 1984;27:737–740.
86. Lung BE, Yelika SB, Murthy AS, Gachabayov M, Denoya P. Cecal bascule: a systematic review of the literature. *Tech Coloproctol*. 2018;22:75–80.
87. Geller A, Petersen BT, Gostout CJ. Endoscopic decompression for acute colonic pseudo-obstruction. *Gastrointest Endosc*. 1996;44:144–150.
88. Ponc RJ, Saunders MD, Kimmey MB. Neostigmine for the treatment of acute colonic pseudo-obstruction. *N Engl J Med*. 1999;341:137–141.

89. Boobés K, Rosa RM, Battle D. Hypokalemia associated with acute colonic pseudo-obstruction in an ESRD patient. *Clin Nephrol.* 2017;87 (2017):152–156.
90. Charatcharoenwithaya P, Pausawasdi N, Pongpaibul A. Education and Imaging: gastrointestinal: Ogilvie's syndrome: a rare complication of cytomegalovirus infection in an immunocompetent patient. *J Gastroenterol Hepatol.* 2014;29:1752.
91. García López CA, Laredo-Sánchez F, Malagón-Rangel J, Flores-Padilla MG, Nellen-Hummel H. Intestinal pseudo-obstruction in patients with systemic lupus erythematosus: a real diagnostic challenge. *World J Gastroenterol.* 2014;20:11443–11450.
92. Lee KJ, Jung KW, Myung SJ, et al. The clinical characteristics of colonic pseudo-obstruction and the factors associated with medical treatment response: a study based on a multicenter database in Korea. *J Korean Med Sci.* 2014;29:699–703.
93. Tsai WC, Chuang TY, Chen MC, Chen JC, Tsao YT. Ogilvie syndrome: a potentially life-threatening phenotype of immobilization hypercalcemia. *Am J Emerg Med.* 2014;32:816.e1–816.e3.
94. Wu J, Wang Y, Wang C. Amyloidosis: an unusual cause of intestinal pseudo-obstruction. *Clin Gastroenterol Hepatol.* 2018;16:e53–e54.
95. Beattie GC, Peters RT, Guy S, Mendelson RM. Computed tomography in the assessment of suspected large bowel obstruction. *ANZ J Surg.* 2007;77:160–165.
96. Chapman AH, McNamara M, Porter G. The acute contrast enema in suspected large bowel obstruction: value and technique. *Clin Radiol.* 1992;46:273–278.
97. Godfrey EM, Addley HC, Shaw AS. The use of computed tomography in the detection and characterisation of large bowel obstruction. *N Z Med J.* 2009;122:57–73.
98. Jaffe T, Thompson WM. Large-bowel obstruction in the adult: classic radiographic and CT findings, etiology, and mimics. *Radiology.* 2015;275:651–663.
99. Munro A, Youngson GG. Colonoscopy in the diagnosis and treatment of colonic pseudo-obstruction. *J R Coll Surg Edinb.* 1983;28:391–393.
100. Eisen GM, Baron TH, Dominitz JA, et al; Standards of Practice Committee of the American Society for Gastrointestinal Endoscopy. Acute colonic pseudo-obstruction. *Gastrointest Endosc.* 2002;56:789–792.
101. Loftus CG, Harewood GC, Baron TH. Assessment of predictors of response to neostigmine for acute colonic pseudo-obstruction. *Am J Gastroenterol.* 2002;97:3118–3122.
102. Sloyer AF, Panella VS, Demas BE, et al. Ogilvie's syndrome. Successful management without colonoscopy. *Dig Dis Sci.* 1988;33:1391–1396.
103. Ross SW, Oommen B, Wormer BA, et al. Acute colonic pseudo-obstruction: defining the epidemiology, treatment, and adverse outcomes of Ogilvie's syndrome. *Am Surg.* 2016;82:102–111.
104. Wegener M, Börsch G, Schmidt G. [Acute pseudo-obstruction of the colon—significance of colonoscopy for diagnosis and therapy]. *Z Gastroenterol.* 1985;23:551–556.
105. Fresenius Kabi. Neostigmine Methylsulfate Injection Approval. US Food and Drug Administration; 2015.
106. van der Spoel JI, Oudemans-van Straaten HM, Stoutenbeek CP, Bosman RJ, Zandstra DF. Neostigmine resolves critical illness-related colonic ileus in intensive care patients with multiple organ failure—a prospective, double-blind, placebo-controlled trial. *Intensive Care Med.* 2001;27:822–827.
107. Amaro R, Rogers AI. Neostigmine infusion: new standard of care for acute colonic pseudo-obstruction? *Am J Gastroenterol.* 2000;95:304–305.
108. Cronnelly R, Stanski DR, Miller RD, Sheiner LB, Sohn YJ. Renal function and the pharmacokinetics of neostigmine in anesthetized man. *Anesthesiology.* 1979;51:222–226.
109. Paran H, Silverberg D, Mayo A, Shwartz I, Neufeld D, Freund U. Treatment of acute colonic pseudo-obstruction with neostigmine. *J Am Coll Surg.* 2000;190:315–318.
110. Mehta R, John A, Nair P, et al. Factors predicting successful outcome following neostigmine therapy in acute colonic pseudo-obstruction: a prospective study. *J Gastroenterol Hepatol.* 2006;21:459–461.
111. İlban Ö, Çiçekçi F, Çelik JB, Baş MA, Duman A. Neostigmine treatment protocols applied in acute colonic pseudo-obstruction disease: a retrospective comparative study. *Turk J Gastroenterol.* 2019;30:228–233.
112. Smedley LW, Foster DB, Barthol CA, Hall R, Gutierrez GC. Safety and efficacy of intermittent bolus and continuous infusion neostigmine for acute colonic pseudo-obstruction. *J Intensive Care Med.* 2020;35:1039–1043.
113. Frankel A, Gillespie C, Lu CT, Hewett P, Wattchow D. Subcutaneous neostigmine appears safe and effective for acute colonic pseudo-obstruction (Ogilvie's syndrome). *ANZ J Surg.* 2019;89:700–705.
114. Kram B, Greenland M, Grant M, Campbell ME, Wells C, Sommer C. Efficacy and safety of subcutaneous neostigmine for ileus, acute colonic pseudo-obstruction, or refractory constipation. *Ann Pharmacother.* 2018;52:505–512.
115. Tahir M, Singh A, Amjad W. Methylxantrexone for neostigmine-resistant Ogilvie syndrome. *Am J Ther.* 2018;25:e727–e728.
116. Weinstock LB, Chang AC. Methylxantrexone for treatment of acute colonic pseudo-obstruction. *J Clin Gastroenterol.* 2011;45:883–884.
117. Jain A, Vargas HD. Advances and challenges in the management of acute colonic pseudo-obstruction (Ogilvie syndrome). *Clin Colon Rectal Surg.* 2012;25:37–45.
118. Bode WE, Beart RW Jr, Spencer RJ, Culp CE, Wolff BG, Taylor BM. Colonoscopic decompression for acute pseudoobstruction of the colon (Ogilvie's syndrome). Report of 22 cases and review of the literature. *Am J Surg.* 1984;147:243–245.
119. Tsirline VB, Zemlyak AY, Avery MJ, et al. Colonoscopy is superior to neostigmine in the treatment of Ogilvie's syndrome. *Am J Surg.* 2012;204:849–855.
120. Peker KD, Cikota M, Bozkurt MA, et al. Colonoscopic decompression should be used before neostigmine in the treatment of Ogilvie's syndrome. *Eur J Trauma Emerg Surg.* 2017;43:557–566.
121. Mankaney GN, Sarvepalli S, Arora Z, et al. Colonic decompression reduces proximal acute colonic pseudo-obstruction and related symptoms. *Dis Colon Rectum.* 2020;63:60–67.
122. Batke M, Cappell MS. Adynamic ileus and acute colonic pseudo-obstruction. *Med Clin North Am.* 2008;92:649–70, ix.
123. Ramage JJ Jr, Baron TH. Percutaneous endoscopic cecostomy: a case series. *Gastrointest Endosc.* 2003;57:752–755.
124. Lynch CR, Jones RG, Hilden K, Wills JC, Fang JC. Percutaneous endoscopic cecostomy in adults: Guyatta case series. *Gastrointest Endosc.* 2006;64:279–282.
125. Rex DK. Colonoscopy and acute colonic pseudo-obstruction. *Gastrointest Endosc Clin N Am.* 1997;7:499–508.
126. Geelhoed GW. Colonic pseudo-obstruction in surgical patients. *Am J Surg.* 1985;149:258–265.