CLINICAL PRACTICE GUIDELINES

The American Society of Colon and Rectal Surgeons Clinical Practice Guidelines for the Management of Anorectal Abscess, Fistula-in-Ano, and Rectovaginal Fistula

Wolfgang B. Gaertner, M.D., M.Sc.[1] • Pamela L. Burgess, M.D.[2]
Jennifer S. Davids, M.D.[3] • Amy L. Lightner, M.D.[4] • Benjamin D. Shogan, M.D.[5]
Mark Y. Sun, M.D.[1] • Scott R. Steele, M.D., M.B.A.[4] • Ian M. Paquette, M.D.[6]
Daniel L. Feingold, M.D.[7]

On behalf of the Clinical Practice Guidelines Committee of the American Society of Colon and Rectal Surgeons
1 Division of Colon and Rectal Surgery, University of Minnesota, Minneapolis, Minnesota
2 Department of Surgery, Uniformed Services University of the Health Sciences, Eisenhower Army Medical Center, Fort Gordon, Georgia
3 Department of Surgery, University of Massachusetts, Worcester, Massachusetts
4 Department of Colon and Rectal Surgery, Cleveland Clinic, Cleveland, Ohio
5 Department of Surgery, University of Chicago, Chicago, Illinois
6 Department of Surgery, University of Cincinnati, Cincinnati, Ohio
7 Division of Colorectal Surgery, Rutgers University, New Brunswick, New Jersey

The American Society of Colon and Rectal Surgeons (ASCRS) is dedicated to ensuring high-quality patient care by advancing the science and prevention and management of disorders and diseases of the colon, rectum, and anus. The Clinical Practice Guidelines Committee is composed of ASCRS members who are chosen because they have demonstrated expertise in the specialty of colon and rectal surgery. This committee was created to lead international efforts in defining quality care for conditions related to the colon, rectum, and anus and develop clinical practice guidelines based on the best available evidence. Although not proscriptive, these guidelines provide information on which decisions can be made and do not dictate a specific form of treatment. These guidelines are intended for the use of all practitioners, health care workers, and patients who desire information on the management of the conditions addressed by the topics covered in these guidelines. These guidelines should not be deemed inclusive of all proper methods of care nor exclusive of methods of care reasonably directed toward obtaining the same results. The ultimate judgment regarding the propriety of any specific procedure must be made by the physician considering all the circumstances presented by the individual patient.

CME Earn Continuing Education (CME) credit online at cme.lww.com. This activity has been approved for AMA PRA Category I credit.™

Funding/Support: None declared.

Financial Disclosure: Dr Gaertner received proctor and speaker fees from Intuitive Surgical, advisory board and consultant fees from Coloplast, consultant fees from Applied Medical, and advisory board and consultant fees from Becton Dickinson. Dr Lightner received consultant fees from Takeda Pharmaceuticals, Ossium Health, and Mesoblast Ltd.

Correspondence: Daniel L. Feingold, M.D., Division of Colorectal Surgery, Rutgers Robert Wood Johnson Medical School, Rutgers University, New Brunswick, 125 Paterson St, MEB 456, New Brunswick, NJ 08901. E-mail: daniel.feingold@rutgers.edu

Dis Colon Rectum 2022; 65: 964–985
DOI: 10.1097/DCR.0000000000002473
© The ASCRS 2022

STATEMENT OF THE PROBLEM

A generally accepted explanation for the cause of anorectal abscess and fistula-in-ano is that an abscess results from obstruction of an anal gland and that a fistula is caused by chronic infection and epithelialization of the abscess drainage tract.[1–4] Anorectal abscesses are described by the anatomic space in which they develop; ischiorectal (also called ischioanal) abscesses are the most common followed by intersphincteric, supralevator, and submucosal locations.[5–8] Anorectal abscess occurs more often in males than females, and although an abscess may develop at any age, the peak incidence is among 20- to 40-year-olds.[4,8–12]

Copyright © The American Society of Colon & Rectal Surgeons, Inc. Unauthorized reproduction of this article is prohibited.

In general, an abscess is treated with prompt incision and drainage.[4,6,10,13] The diagnosis and treatment of necrotizing soft tissue infections and Fournier's gangrene are beyond the scope of this guideline.

Fistula-in-ano is an epithelialized tract that connects the perianal skin with the anal canal. In patients with an anorectal abscess, 30% to 70% present with a concomitant fistula-in-ano, and, of those who do not, approximately 30% to 50% will ultimately be diagnosed with a fistula in the months to years after abscess drainage.[2,5,8–10,13–16] Although an anorectal abscess is described by the anatomic space in which it forms, a fistula-in-ano is classified in terms of its relationship with the internal and external anal sphincters (eg, the Parks classification; Table 1).[16] In general, intersphincteric and transsphincteric fistulas are more frequently encountered than suprasphincteric, extrasphincteric, and submucosal tract locations.[9,17–19] Anal fistulas may also be classified as "simple" or "complex."[20,21] Complex anal fistulas include transsphincteric fistulas that involve greater than 30% of the external sphincter, suprasphincteric, extrasphincteric, or horseshoe fistulas and anal fistulas associated with IBD, radiation, malignancy, preexisting fecal incontinence, or chronic diarrhea.[20–22] Recurrent or branching fistulas may also be described as complex. Given the attenuated nature of the anterior sphincter in women, anterior fistulas deserve special consideration and may also be considered complex. Simple anal fistulas have none of these complex features and, in general, include intersphincteric and low transsphincteric fistulas that involve less than 30% of the external sphincter.

Distinct from cryptoglandular processes, anorectal abscess and fistula-in-ano can be manifestations of Crohn's disease. Among patients with Crohn's disease, fistula-in-ano has an incidence rate of 10% to 20% in population-based studies and 50% in longitudinal studies; meanwhile, nearly 80% of patients with Crohn's disease who were cared for at tertiary referral centers may have a history of fistula-in-ano.[23,24] In Crohn's disease, anorectal abscesses and fistulas seem to result from penetrating inflammation rather than from infection of an anorectal gland.[25] Patients with fistulas related to Crohn's disease are typically managed with a multidisciplinary approach.[26]

Rectovaginal fistulas (RVFs), a unique subset of fistulas in many respects, may be classified as "low," with a tract between the distal anal canal (at or below the dentate line) and the inside of the posterior fourchette; "high," with a tract connecting the upper vagina (at the level of the cervix) with the rectum; and "middle" with a tract that lies in between these levels.[27–29] The terms "anovaginal fistula" and "low rectovaginal fistula" may be used interchangeably. RVFs may also be classified as "simple" or "complex." Simple RVFs have a low, small-diameter (<2 cm) communication between the anal canal and vagina and typically result from obstetrical injury or infection.[29] "Complex" RVFs involve a higher tract between the rectum and vagina, are of a larger diameter, or result from radiation, cancer, or complications of pelvic surgical procedures.[30–33] RVFs most commonly occur as a result of obstetric injury[29] but may also occur in the setting of Crohn's disease,[25] malignancy, or infection,[32] or as a complication of a failed colorectal anastomosis,[33] an anorectal operation,[34] or radiation therapy.[35]

The surgical treatment of a particular fistula is influenced by the patient's presenting symptoms, unique anatomy of the fistula tract, quality of the surrounding tissues, and previous attempts at fistula repair.[36] This guideline addresses the management of cryptoglandular fistulas, RVFs, and anorectal fistulas in the setting of Crohn's disease.

TABLE 1. Parks classification of fistula-in-ano

Fistula type	*Description*
Submucosal	Superficial fistula tract. Does not involve any sphincter muscle.
Intersphincteric	Crosses the internal sphincter and then has a tract to the perianal skin. Does not involve any external anal sphincter muscle.
Transsphincteric	Tracks from the internal opening at the dentate line via the internal and external anal sphincters and then terminates in the perianal skin or perineum.
Suprasphincteric	Courses superiorly into the intersphincteric space over the top of the puborectalis muscle and then descends through the iliococcygeus muscle into the ischiorectal fossa and into the perianal skin.
Extrasphincteric	Passes from the perineal skin through the ischiorectal fossa and levator muscles and then into the rectum and lies completely outside the external sphincter complex.

Adapted from Parks et al.[16]

MATERIALS AND METHODS

These guidelines were built on the last clinical practice guidelines for the management of anorectal abscess and fistula-in-ano published in 2016.[37] An organized search was performed of MEDLINE, PubMed, Embase, and the Cochrane Database of Systematic Reviews between December 1, 2015, and November 5, 2021. Key word combinations using MeSH terms included abscess, fistula, fistula-in-ano, anal, rectal, perianal, perineal, rectovaginal, anovaginal, seton, fistulotomy, stem cell, advancement flap, ligation of intersphincteric fistula tract (LIFT), fistula plug, fistula glue, video-assisted anal fistula treatment (VAAFT), fistula laser closure (FiLaC), over-the-scope clip (OTSC) device, and Crohn's disease. The search was restricted to English-language articles and studies of adult patients. Directed searches using embedded references from primary articles were performed in selected circumstances, and other sources including practice guidelines and consensus statements from relevant societies were also reviewed. The 841 screened articles were evaluated for

Copyright © The American Society of Colon & Rectal Surgeons, Inc. Unauthorized reproduction of this article is prohibited.

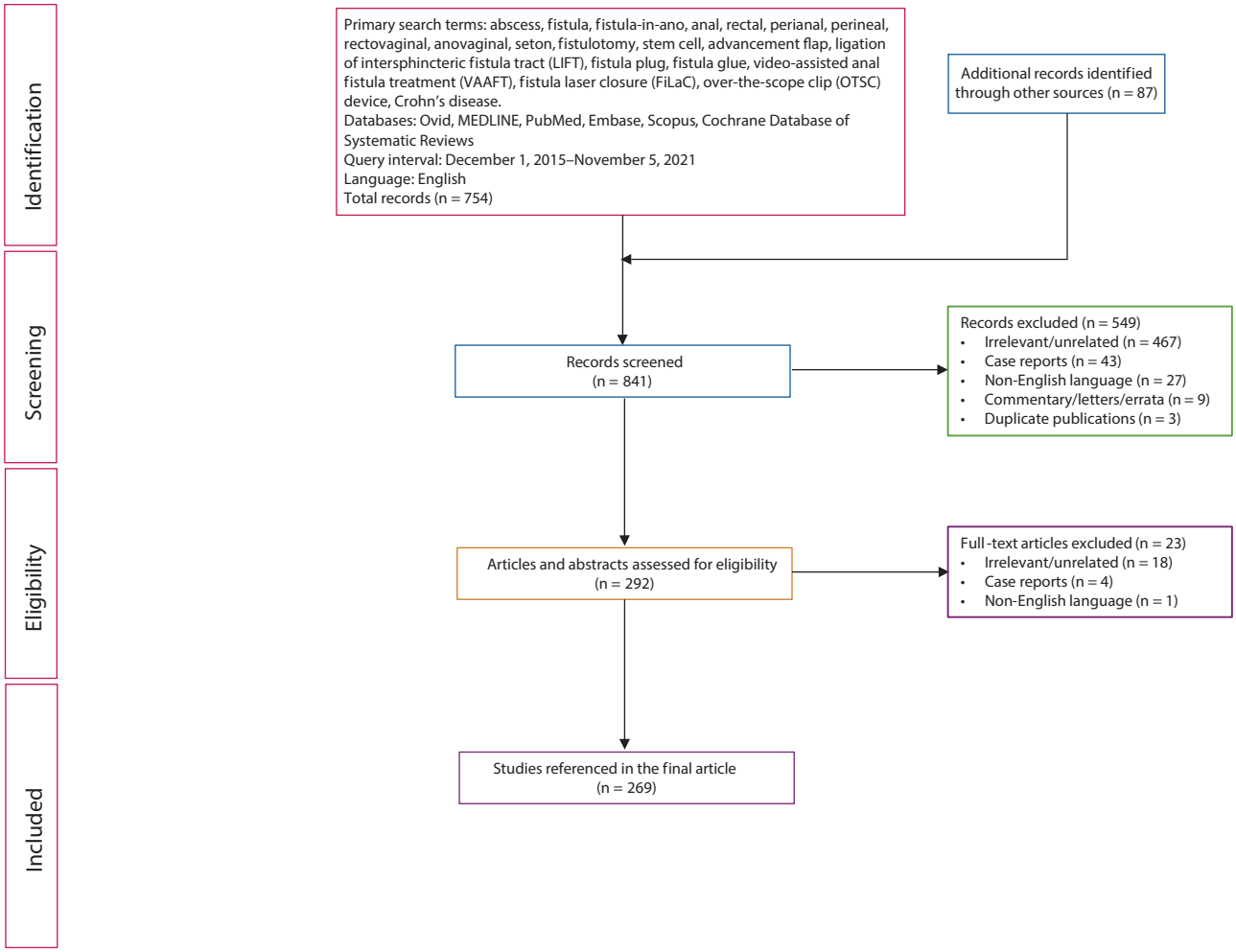

FIGURE 1. PRISMA literature search flow sheet. PRISMA = Preferred Reporting Items for Systematic Reviews and Meta-Analyses.

their level of evidence, favoring clinical trials, meta-analysis/systematic reviews, comparative studies, and large registry retrospective studies during single-institutional series, retrospective reviews, and peer-reviewed, observational studies. A final list of 269 sources was evaluated for methodologic quality, the evidence base was analyzed, and a treatment guideline was formulated by the subcommittee for this guideline (Fig. 1). The final grade of recommendation and level of evidence for each statement were determined using the Grades of Recommendation, Assessment, Development, and Evaluation system (Table 2). When the agreement was incomplete regarding the evidence base or treatment guideline, consensus from the committee chair, vice chair, and 2 assigned reviewers determined the outcome. Members of the ASCRS Clinical Practice Guidelines Committee worked in joint production of these guidelines from inception to final publication (Table 3). The entire Clinical Practice Guidelines Committee reviewed the recommendations formulated by the subcommittee. Final recommendations were approved by the ASCRS Executive Council. In general, each ASCRS Clinical Practice Guideline is updated every 5 years. No funding was received for preparing this guideline, and the authors have declared no competing interests related to this material. This guideline conforms to the Appraisal of Guidelines for Research and Evaluation checklist.

Initial Evaluation of Anorectal Abscess and Fistula

1. A disease-specific history and physical examination should be performed evaluating symptoms, relevant history, abscess and fistula location, and presence of secondary cellulitis. Grade of recommendation: strong recommendation based on low-quality evidence, 1C.

Anorectal abscess is usually diagnosed on the basis of a patient's history and physical examination. Anorectal pain and swelling are common with superficial abscesses, whereas spontaneous drainage and fever occur less often.[8–10,38] Deeper abscesses, including those in the supralevator or high ischiorectal spaces, may present with pain referred to the perineum, lower back, or buttocks.[6,39,40] Evaluation of the anus and perineum may reveal erythema, calor,

Copyright © The American Society of Colon & Rectal Surgeons, Inc. Unauthorized reproduction of this article is prohibited.

TABLE 2. The GRADE system: grading recommendations

	Description	*Benefit versus risk and burdens*	*Methodologic quality of supporting evidence*	*Implications*
1A	Strong recommendation, high-quality evidence	Benefits clearly outweigh risks and burdens or vice versa	RCTs without important limitations or overwhelming evidence from observational studies	Strong recommendation, can apply to most patients in most circumstances without reservation
1B	Strong recommendation, moderate-quality evidence	Benefits clearly outweigh risks and burdens or vice versa	RCTs with important limitations (inconsistent results, methodologic flaws, indirect or imprecise) or exceptionally strong evidence from observational studies	Strong recommendation, can apply to most patients in most circumstances without reservation
1C	Strong recommendation, low- or very-low quality evidence	Benefits clearly outweigh risks and burdens or vice versa	Observational studies or case series	Strong recommendation but may change when higher-quality evidence becomes available
2A	Weak recommendation, high-quality evidence	Benefits closely balanced with risks and burdens	RCTs without important limitations or overwhelming evidence from observational studies	Weak recommendation, best action may differ depending on circumstances or patients' values or societal values
2B	Weak recommendation, moderate-quality evidence	Benefits closely balanced with risks and burdens	RCTs with important limitations (inconsistent results, methodologic flaws, indirect or imprecise) or exceptionally strong evidence from observational studies	Weak recommendation, best action may differ depending on circumstances or patients' values or societal values
2C	Weak recommendation, low- or very-low quality evidence	Uncertainty in the estimates of benefits, risks, and burdens; benefits, risks, and burdens may be closely balanced	Observational studies or case series	Very weak recommendations; other alternatives may be equally reasonable

GRADE = Grades of Recommendation, Assessment, Development, and Evaluation; RCT = randomized controlled trial.
Adapted from Guyatt et al.[38] Used with permission.

fluctuance, cellulitis, or tenderness on palpation or may be relatively unrevealing, particularly in patients with intersphincteric or deeper abscesses,[6,10,40,41] and digital rectal examination and anoscopy/proctoscopy are occasionally needed to clarify the diagnosis. The differential diagnosis of anorectal abscess may include fissure, hemorrhoid thrombosis, pilonidal disease, hidradenitis, anorectal neoplasia, Crohn's disease, and sexually transmitted infections.[6,42,43] Patients who present with anal fistula typically report intermittent anorectal swelling and drainage. Relevant information about baseline anal sphincter function, history of anorectal operations, family history of IBD, obstetric history, and associated GI, genitourinary, or gynecologic pathology should typically be included in the patient's history.

Inspection of the perineum should involve noting the specific findings of an abscess, surgical scars, anorectal deformities, signs of possible anorectal Crohn's disease, and the presence of an external fistula opening. Gentle probing of an external opening, when tolerated, may help confirm the presence of a fistula tract but should be done with care to avoid creating false tracts.[43] Goodsall's rule, that an anterior fistula-in-ano has a radial tract and a posterior fistula has a curvilinear tract to the anus, has generally proven to be accurate for anterior fistulas but is less accurate in cases with a posterior fistula.[44–47]

2. **Routine use of diagnostic imaging is not typically necessary for patients with anorectal abscess or fistula. However, imaging may be considered in selected patients with an occult anorectal abscess, recurrent or complex anal fistula, immunosuppression, or anorectal Crohn's disease. Grade of recommendation: strong recommendation based on moderate-quality evidence, 1B.**

In a retrospective study of 113 patients with anorectal abscess, the overall sensitivity of CT for detecting an abscess was 77% and the sensitivity of CT in immunosuppressed patients was 70%.[48] An advantage of MRI over CT is its ability to identify anorectal abscesses and associated fistula tracts. In a study of 54 patients with anorectal Crohn's disease, in which MRI and operative/clinical findings were compared, all the abscesses and 82% of the fistulas were correctly identified by MRI.[49] In a 2014 prospective study of 50 patients with suspected anorectal fistula, MRI had a 95% sensitivity, 80% specificity, and 97% positive predictive value in detecting and grading the primary fistula tract.[50] In a retrospective study of 136 patients specifically looking at the role of MRI in the preoperative assessment of fistula patients, Konan et al[51] found that MRI identified "significant" findings defined as secondary (blind) tracts, horseshoe abscesses, or abscesses undiagnosed by physical

Copyright © The American Society of Colon & Rectal Surgeons, Inc. Unauthorized reproduction of this article is prohibited.

TABLE 3. What is new in the 2022 ASCRS Clinical Practice Guidelines for the management of anorectal abscess, fistula-in-ano, and rectovaginal fistula?

2022 New recommendations
11. Minimally invasive approaches to treat fistula-in-ano that use endoscopic or laser closure techniques have reasonable short-term healing rates but unknown long-term fistula healing and recurrence rates. Grade of recommendation: weak recommendation based on low-quality evidence, 2C.
19. Anorectal fistula associated with Crohn's disease is typically managed with a combination of surgical and medical approaches. Grade of recommendation: strong recommendation based on moderate-quality evidence, 1B.
25. Local administration of mesenchymal stem cells is a safe and effective treatment for selected patients with refractory anorectal fistulas in the setting of Crohn's disease. Grade of recommendation: weak recommendation based on moderate-quality evidence, 2B.
2022 Updated recommendations
5. Antibiotics should typically be reserved for patients with an anorectal abscess complicated by cellulitis, systemic signs of infection, or underlying immunosuppression. Grade of recommendation: weak recommendation based on moderate-quality evidence, 2C→2B.
9. A cutting seton may be used selectively in the management of complex cryptoglandular anal fistulas. Grade of recommendation: weak recommendations based on low-quality evidence, 2B→2C.
10. The anal fistula plug and fibrin glue are relatively ineffective treatments for fistula-in-ano. Grade of recommendation: strong recommendation based on moderate-quality evidence, 2B→1B.
21. Draining setons are typically useful in the multimodality therapy of fistulizing anorectal Crohn's disease and may be used for long-term disease control. Grade of recommendation: strong recommendation based upon moderate-quality evidence, 1C→1B.
22. Symptomatic, simple, low anal fistulas in carefully selected patients with Crohn's disease may be treated by lay-open fistulotomy. Grade of recommendation: weak recommendation based on low-quality evidence, 1C→ 2C.
23. Endorectal advancement flaps and the LIFT procedure may be used to treat fistula-in-ano associated with Crohn's disease. Grade of recommendation: strong recommendation based on moderate-quality evidence, 2B→1B.

ASCRS = American Society of Colon and Rectal Surgeons; LIFT = ligation of intersphincteric fistula tract.

examination or examination under anesthesia in 34% of patients. In this study, MRI provided significant findings more frequently for complex fistulas than for simple fistulas (54% vs 5%; $p < 0.001$). Additionally, the proportion of patients who had significant MRI contributions increased with increasing Parks grade (5% for grade 1; 48% for grade 2; 86% for grade 3; 87.5% for grade 4). A prospective trial published in 2019, including 126 patients, assessed the utility of 3-dimensional endoanal ultrasound (EAUS) and MRI in both simple (n = 68) and complex (n = 58) anal fistulas and reported comparable accuracy for the 2 modalities in cases of a simple fistula; however, MRI had significantly higher sensitivity evaluating secondary extensions in complex fistulas (97% vs 74%; $p = 0.04$).[52]

Endoanal ultrasound, in 2 or 3 dimensions and with or without peroxide enhancement, may be useful in the management of patients with abscess or fistula, and studies demonstrate concordance between EAUS and operative findings in 73% to 100% of cases.[53–55] Tantiphlachiva et al[56] found that preoperative EAUS may help preserve anorectal function in patients undergoing anal fistula surgery. This study retrospectively evaluated pre- and postoperative Fecal Incontinence Severity Scores in 109 patients who underwent preoperative EAUS and in 230 patients without preoperative imaging and found significantly worse Fecal Incontinence Severity Scores in the group that did not undergo preoperative EAUS at a mean follow-up of 34 weeks. The potential added value of combining diagnostic modalities to enhance the accuracy of anal fistula assessment was exemplified in a 2001 blinded study of 34 patients with anorectal Crohn's disease in which EAUS was accurate in 91% of patients, MRI was accurate in 87% of patients, and examination under anesthesia was accurate in 91% of patients, whereas 100% accuracy was achieved when any 2 techniques were combined.[57]

The sensitivity, accuracy, and utility of transperineal ultrasound (TPUS), a noninvasive alternative to EAUS, have also been studied in patients with anorectal abscess, anoperineal fistulas, and RVFs.[58–61] A prospective study of 23 patients with Crohn's disease comparing the diagnostic accuracies of EAUS, TPUS, and MRI with operative findings found that the diagnostic accuracy of all 3 modalities was nearly identical.[62] The authors concluded that TPUS might be considered first-line imaging because of its availability, low cost, and noninvasive nature, yet because of its operator dependency and lack of high-quality supporting data, this imaging technique has not gained widespread popularity.

Anorectal Abscess

3. Patients with acute anorectal abscess should be treated promptly with incision and drainage. Grade of recommendation: strong recommendation based on low-quality evidence, 1C.

The primary treatment of anorectal abscess remains surgical drainage. In general, the incision should be made large enough to provide adequate drainage while taking care not to injure the anal sphincter complex. The perianal incision should be kept as close as possible to the anal verge to minimize the length of a subsequent fistula tract should one develop. Alternatively, a surgical drain (eg, Pezzer, Malecot) can be placed into the abscess cavity[63,64] if this provides adequate drainage, although this technique typically does not address loculations within an abscess cavity and generally omits primary fistulotomy.

Copyright © The American Society of Colon & Rectal Surgeons, Inc. Unauthorized reproduction of this article is prohibited.

Small comparative analyses have shown comparable efficacy and higher patient satisfaction with drain placement compared to incision and drainage.[65–67] Once an abscess has been drained, randomized trials report equivalent or superior abscess resolution rates with less pain and faster healing in patients whose wounds were left unpacked.[68,69]

After drainage, abscesses may recur in up to 44% of patients, most often within 1 year of initial treatment.[2,10,70] Inadequate drainage, the presence of loculations or a horseshoe-type abscess, and not performing a primary fistulotomy are risk factors for recurrent abscess (primary fistulotomy is further addressed in recommendation no. 4).[10,71,72]

Abscess location generally determines whether a patient should have internal versus external drainage. Intersphincteric abscesses should typically be drained through the intersphincteric groove or into the anal canal via an internal sphincterotomy.[69] Similarly, it is usually preferable to drain supralevator abscesses originating from the complicated extension of an intersphincteric abscess internally by incising the rectal wall to prevent fistula formation. Meanwhile, supralevator abscesses because of cephalad extension of an ischiorectal abscess should typically be drained externally through the perianal skin.[16,71] These approaches to abscess drainage may help prevent complex fistula formation.

Abscesses that cross the midline (ie, horseshoe) can be challenging to manage. These abscesses most often involve the deep postanal space and extend laterally into the ischiorectal spaces.[40,71] Under these circumstances, primary lay-open fistulotomy should typically be avoided because these fistulas tend to be transsphincteric. The Hanley procedure, a technique that drains the deep postanal space and uses counter incisions to address the ischiorectal spaces, is effective in the setting of a horseshoe abscess,[71] although it may negatively impact anal sphincter function.[40,71] A modified Hanley technique using a posterior midline partial sphincterotomy to unroof the postanal space plus seton placement has a high rate of abscess resolution and has been reported to better preserve anorectal function compared to other operative interventions.[40,72,73]

4. Abscess drainage with concomitant fistulotomy may be performed in selected patients with simple anal fistulas. Grade of recommendation: weak recommendation based on moderate-quality evidence, 2B.

Although 30% to 70% of patients with anorectal abscesses present with a concomitant fistula-in-ano,[10,11] the role of primary fistulotomy at the time of abscess drainage remains controversial. Although a fistulotomy may effectively address the offending crypt, edema and inflammation from the suppurative process may increase the risk of causing a false tract when probing a fistula and can make it difficult to accurately assess the anatomy, potentially causing the surgeon to underestimate the degree of sphincter involvement. Small, randomized studies evaluating primary fistulotomy have reported varied results with regard to fistula recurrence and fecal incontinence.[12,74,75]

Schouten and van Vroonhoven,[12] in a randomized controlled trial, found that of 36 patients treated with primary fistulectomy and partial internal sphincterotomy only 3% had recurrence, whereas 39% reported postoperative sphincter disturbance at a median follow-up of 42 months; meanwhile, of 34 patients treated with incision and drainage alone, 41% had recurrence and 21% reported postoperative functional disturbance. Bokhari and Lindsey,[74] in a retrospective review of 128 patients treated with either fistulotomy or sphincter preservation, found that after treatment, major incontinence was significantly more common in patients who had a complex fistula (13%) compared to those who had a simple fistula (5%). A 2010 Cochrane review that included 479 patients pooled from 6 randomized controlled trials demonstrated that sphincter division (via fistulotomy or fistulectomy) at the time of incision and drainage was associated with a significantly decreased likelihood of abscess recurrence, persistence of fistula or abscess, or need for subsequent surgery (relative risk, 0.13; 95% CI, 0.07–0.24) but an increased, albeit not statistically significant, incidence of continence disturbance at 1-year follow-up.[75] Notably, the randomized trials included in this meta-analysis excluded patients with complex fistulas, recurrent abscesses, IBD, preexisting incontinence, or history of anorectal surgery and included patients with low fistulas.

Given the potential negative consequences of a fistulotomy, some surgeons have advocated performing a partial fistulotomy with placement of a draining seton through the remaining tract. A retrospective review evaluated the outcomes of 26 patients with low transsphincteric fistulas who underwent partial fistulotomy and then draining seton placement (23 patients were male). Postoperatively, patients who had preserved anal sphincter function underwent a staged, completion fistulotomy. This study reported that at 1 year, all 24 patients who underwent staged fistulotomy reported no fistula or abscess recurrence or incontinence, supporting the approach of temporary seton placement followed by staged fistulotomy in selected patients with a low transsphincteric fistula.[76]

When a simple fistula is encountered during incision and drainage of an anorectal abscess, fistulotomy may be performed in selected patients provided that the anticipated benefit of healing outweighs the potential risk of fecal incontinence.[1,4,5] However, placing a draining seton to treat a fistula discovered at the time of incision and drainage requires patients to proceed with a staged procedure to address their fistula.[4,11,77]

5. Antibiotics should typically be reserved for patients with an anorectal abscess complicated by cellulitis, systemic signs of infection, or underlying immunosuppression. Grade of recommendation:

Copyright © The American Society of Colon & Rectal Surgeons, Inc. Unauthorized reproduction of this article is prohibited.

weak recommendation based on moderate-quality evidence, 2B.

In general, administering antibiotics after performing an incision and drainage of a routine, uncomplicated anorectal abscess in a healthy patient does not improve healing or reduce the recurrence rate and is typically not recommended. However, antibiotics may be used selectively in patients with an anorectal abscess complicated by cellulitis, systemic illness, or underlying immunosuppression.[4,10,13,78,79] Given the available evidence, the grade of this clinical practice guideline recommendation was changed from a 2C grade in 2016 to a 2B grade.

A retrospective study of 172 patients with "uncomplicated" anorectal abscess who underwent incision and drainage with (n = 64) or without (n = 108) subsequent oral antibiotic therapy for 5 to 7 days reported that 9% of all patients required repeat surgery related to anorectal infection, but there was no significant difference between the groups in this regard.[80] Patients with surrounding cellulitis, induration, or signs of systemic sepsis who did not receive antibiotics had a 2-fold increase in the rate of recurrent abscess compared with patients who received antibiotics, although this did not meet statistical significance. The authors also concluded that routinely culturing abscesses does not affect management or outcomes.[80]

A 2017 study evaluated the impact of postoperative antibiotics on fistula formation after incision and drainage of an anorectal abscess. In this single-blinded, randomized trial by Ghahramani and colleagues,[81] 307 patients were treated with incision and drainage with or without a 7-day postoperative course of ciprofloxacin and metronidazole. At 3-month follow-up, 14% of patients in the antibiotic treatment group developed an anal fistula versus 30% in the control group ($p < 0.001$). Contrary to this study, Sözener et al[13] studied 334 patients in a randomized, placebo-controlled, double-blinded multicenter trial who showed no protective effect of antibiotics with regard to anal fistula formation.

Although routinely culturing anorectal abscesses is not considered clinically useful, methicillin-resistant *Staphylococcus aureus* has been reported in up to 33% of patients.[80,82,83] When methicillin-resistant *Staphylococcus aureus* is isolated from an anorectal abscess, a combination of abscess drainage and antibiotics directed against the organism is typically recommended for patients with systemic signs of sepsis, leukocytosis, or leukopenia.[84] Microbial cultures should also be considered in cases of recurrent infection or nonhealing wounds.[80]

Data suggest that antibiotics play an important role in treatment for neutropenic or otherwise immunosuppressed patients with an anorectal abscess.[85–87] Although patients with a higher absolute neutrophil count (ie, >1000/mm^3) and fluctuance on examination typically have high resolution rates with incision and drainage, immunosuppressed patients with lower absolute neutrophil counts and lack of fluctuance on examination may initially be treated with antibiotics alone.[88–90] Patients with underlying HIV infection with concomitant or atypical infections, including tuberculosis, may also benefit from wound culture and targeted antibiotic treatment.[85]

Anal Fistula

The primary goals of operative treatment for fistula-in-ano are to obliterate the internal opening and associated epithelialized tracts and to preserve anal sphincter function. Given that no single technique is appropriate for managing all fistulas, treatment must consider the cause and anatomy of the fistula tract, the degree of symptoms, patients' comorbidities, and surgeons' experience and preference recognizing the interplay between the extent of operative sphincter division and the risks of healing issues, recurrence, and poor functional outcome.

6. Patients with a simple fistula-in-ano and normal anal sphincter function may be treated with lay-open fistulotomy. Grade of recommendation: strong recommendation based on moderate-quality evidence, 1B.

Primary fistulotomy is associated with high patient satisfaction and fistula resolution rates (more than 90%).[11,91,92] Factors related to recurrence after fistulotomy include branching of fistulas, failure to accurately identify the internal opening, and fistulas associated with Crohn's disease.[93,94] Multiple prospective, multicenter studies indicate that when fistulotomy is used for simple, low-lying anal fistulas (ie, involving less than one-third of the external anal sphincter), the risk of clinically significant fecal incontinence is minimal in appropriately selected patients.[14,91] A multicenter, retrospective study including 537 patients with low fistulas (defined by the authors as fistulas limited to the lower one-third of the anal sphincter complex or not involving the sphincter muscles at all) who underwent fistulotomy reported a 28% incidence of major postprocedure fecal incontinence.[95] The retrospective methodology used in this study and the lack of preoperative continence evaluation may have influenced the reported outcomes.

Fistulotomy for high-lying or otherwise complex fistulas may result in significant postoperative incontinence in 10% to 40% of patients.[74,93,96] Risk factors for postoperative anal sphincter dysfunction after fistulotomy include preoperative fecal incontinence, recurrent fistula, female sex, complex fistulas, and previous anorectal surgery.[93,96,97] Women with anterior fistulas or who may have occult sphincter damage from previous birthing trauma are also at risk for sphincter dysfunction after fistulotomy. Interventions other than fistulotomy are generally recommended in patients with the above-mentioned risk factors to preserve function.

Copyright © The American Society of Colon & Rectal Surgeons, Inc. Unauthorized reproduction of this article is prohibited.

Multiple strategies to accelerate wound healing after fistulotomy have been studied. Four randomized controlled trials comparing fistulotomy with and without marsupialization found that marsupialization resulted in less postoperative bleeding and improved wound healing.[98–101] Additionally, topical ointments, such as 10% sucralfate and 2% phenytoin, applied to the fistulotomy site have been associated with decreased postoperative pain and improved healing compared to placebo.[102,103]

Fistulectomy, in which the tract is cored out rather than laid open, has been compared to fistulotomy. A randomized controlled trial published in 1985 (n = 47) found that fistulectomy patients had longer healing times, larger defects, and a higher risk of fecal incontinence compared to patients who underwent fistulotomy but had comparable fistula recurrence rates.[104] A meta-analysis of 6 randomized controlled trials did not offer conclusive evidence that fistulectomy was associated with worse outcomes compared to fistulotomy in patients with low-lying fistulas.[105]

7. Fistula-in-ano may be treated with endorectal advancement flap. Grade of recommendation: strong recommendation based on moderate-quality evidence, 1B.

Endorectal advancement flap procedures consist of curettage of the fistula tract, suture closure of the internal opening, and covering the internal opening with a mobilized segment of rectum. Retrospective series, small clinical trials, and a meta-analysis report healing in 66% to 87% of patients after initial endorectal advancement flap for cryptoglandular fistula.[106–110] Endorectal advancement flap repeated after a failed flap procedure or performed after other failed initial approaches including LIFT is associated with healing rates ranging between 57% and 100%.[106,111,112]

Factors associated with endorectal advancement flap failure include history of pelvic radiation therapy, underlying Crohn's disease, active proctitis, history of abscess drainage, RVF, smoking, malignancy, obesity, and having had more than 1 previous attempted repair.[18,93,109,113–119] A diverting stoma has not been shown to improve outcomes after endorectal advancement flap and is not typically recommended.[18,109]

From a technical standpoint, although care is taken not to injure the anal sphincter with this approach, internal anal sphincter fibers may be included in the flap to preserve blood flow, and mild-to-moderate incontinence has been reported with concomitant decreased manometric resting and squeeze pressures in up to 35% of patients.[110,120,121] Endorectal advancement flaps in the posterior position, especially in men with deep buttocks, can be technically challenging. In patients with fistulas with an internal opening distal to the dentate line, endorectal advancement flap may result in mucosal ectropion; other approaches should be considered in these circumstances.

8. Transsphincteric fistulas may be treated with ligation of the intersphincteric fistula tract (LIFT) procedure. Grade of recommendation: strong recommendation based on moderate-quality evidence, 1B.

The LIFT procedure involves suture ligation and division of a fistula tract in the intersphincteric plane.[122] A draining seton may be used before the LIFT procedure to allow for fibrosis of the tract that may facilitate the procedure, but this has not been shown to affect the success rate of the LIFT procedure.[123] A meta-analysis of 1378 LIFT procedures from 26 studies demonstrated an overall success rate of 76%, an overall complication rate of 14%, and a fecal incontinence rate of 1.4%.[124] In this study, risk factors for failure included horseshoe anatomy, Crohn's disease fistulas, and history of fistula surgery. Other studies evaluating long-term LIFT outcomes have demonstrated lower rates of primary healing, ranging from 42% to 62%[122–128]; however, the LIFT procedure has been associated with significant rates of secondary healing after surgical reintervention (typically fistulotomy for an intersphincteric recurrence) ranging from 77% to 86%.[112,129,130]

Modifications of the LIFT procedure, including excising the lateral aspect of the tract, incorporating a fistula plug or biologic mesh interposition, or using video-assisted techniques, have been described and, in some studies, are associated with improved healing rates compared to the standard LIFT. However, the evidence evaluating these techniques is limited to small studies and such modifications to the standard LIFT technique are typically not recommended.[125,130–134]

9. A cutting seton may be used selectively in the management of complex cryptoglandular anal fistulas. Grade of recommendation: weak recommendation based on low-quality evidence, 2C.

Complex anal fistulas are often treated initially by placing a draining seton to control the local sepsis, followed by a staged, definitive procedure to eradicate the fistula.[131] Healing rates under these circumstances range from 62% to 100%, depending on the type of definitive operation used.[131,135] Alternatively, a cutting seton may be left in place and tightened at intervals, gradually dividing the fistula and any involved anal sphincter.[135] Although not a sphincter-sparing procedure, placement of cutting setons was historically performed when the risk of fecal incontinence from a lay-open fistulotomy was considered to be prohibitively high. Given the available evidence, the grade of this clinical practice guideline recommendation was changed from a 2B grade in 2016 to a 2C grade.

A retrospective study including 121 patients with either low-lying or complex fistulas treated with a cutting seton by a single surgeon showed a 98% fistula healing rate,[136] and only 8 patients (7%) developed incontinence. Other retrospective studies evaluating cutting setons for

Copyright © The American Society of Colon & Rectal Surgeons, Inc. Unauthorized reproduction of this article is prohibited.

transsphincteric and other complex cryptoglandular fistulas have similarly demonstrated high rates of fistula healing (~90%) with preservation of anal sphincter function in the majority of patients.[136,137] Although these results seem promising, an earlier review that pooled 37 studies and included 1460 patients who underwent a cutting seton procedure reported a wide range of postoperative fecal incontinence (0%–67%) and variable functional outcomes depending on the type of fistula tract encountered and the specific definition of fecal incontinence used.[138] Although studies suggest that a cutting seton is efficacious and safe for the treatment of anal fistulas, especially complex fistulas, this technique can result in functional impairment and should be used in carefully selected patients.

10. The anal fistula plug and fibrin glue are relatively ineffective treatments for fistula-in-ano. Grade of recommendation: strong recommendation based on moderate-quality evidence, 1B.

The bioprosthetic anal fistula plug, an acellular collagen matrix used to close the internal fistula opening, provides a scaffold for native tissue in-growth to obliterate a fistula tract. Although early data demonstrated 70% to 100% success with the plug,[139,140] more recently published outcomes have been less encouraging with healing rates of 50% or less.[141–147] Early plug failure, typically attributed to localized sepsis or plug dislodgement, occurred in 4% to 41% of cases in a 2016 systematic review.[146] Plug failure is reported to be more common in patients with Crohn's disease, anovaginal fistula, or recurrent fistula and in active smokers.[148]

In terms of using fibrin glue to treat fistulas, despite historical data with encouraging results,[149] usage of fibrin glue injection for treating anal fistulas has decreased in popularity because of disappointing contemporary data.[150–157] In a 2019 randomized controlled double-blind trial, only 10 of 24 patients (41%) in the fibrin glue treatment arm had complete fistula healing.[158] In a retrospective review of 462 patients who underwent sphincter-preserving surgery for cryptoglandular anal fistula between 2005 and 2015, the use of an anal fistula plug (associated with healing rate of 24%) and fibrin glue (associated with healing rate of 18%) decreased significantly over the interval and the overall fistula healing rate increased significantly from 32% to 64%.[159] Despite the generally poor healing rates associated with fistula plugs and fibrin glue, the possibility of success coupled with the sphincter-preserving nature of these approaches have allowed for their continued albeit selective use. Given the available evidence regarding the anal fistula plug and fibrin glue, this clinical practice guideline recommendation grade has been changed from a 2B grade in 2016 to a 1B grade.

11. Minimally invasive approaches to treat fistula-in-ano that use endoscopic or laser closure techniques have reasonable short-term healing rates but unknown long-term fistula healing and recurrence rates. Grade of recommendation: weak recommendation based on low-quality evidence, 2C.

Minimally invasive techniques to treat anal fistulas have been studied during the past 2 decades to develop approaches with improved outcomes compared to more conventional fistula operations. These techniques, described in small, single-institution series with limited follow-up and with various degrees of industry support, include VAAFT, FiLaC, and endoscopic clipping using an OTSC device. These approaches were not specifically addressed in the 2016 clinical practice guideline, but given the evolving literature evaluating these techniques, the relevant evidence is reviewed in the following.

The majority of institutional experiences with VAAFT have been preliminary. This technique involves fistuloscopy through the external opening to identify the internal opening, closure of the internal orifice with sutures, clips, or a stapling device, and selective debridement or obliteration of the fistula tract. Reported healing rates after VAAFT range from 71% to 85% with follow-up intervals typically <12 months and with minor or no fecal incontinence reported.[160–163]

FiLaC uses a radially emitting laser probe that, when passed along the tract, traumatizes the epithelium and, in theory, obliterates the fistula tract. In a recent meta-analysis, Elfeki and colleagues[164] reviewed 7 case series and comparative studies involving 454 patients (69% had transsphincteric fistulas and 35% had recurrent fistulas) who underwent FiLaC. At a median follow-up of 24 months, 65% of patients were healed, 4% experienced a complication, and the mean rate of incontinence was 1%.

Closure of the internal opening of a fistula tract has also been described using an OTSC device. This approach, frequently combined with a fistuloscopy, places a superelastic nitinol clip over the internal fistula opening with the aid of a transanal applicator. Outcomes of this technique have been reported in small, single-institution reviews that have shown primary healing rates of 79% to 90% with limited follow-up.[165,166] Clip removal to relieve pain has been required in a minority of patients. In a German series including 55 transsphincteric, 38 suprasphincteric, 2 extrasphincteric, and 5 RVFs, the healing rate at 6 months for first-time fistula therapy was 79%, whereas patients with recurrent fistulas had a success rate of 26%.[166]

Rectovaginal Fistula

The initial evaluation of patients with RVFs should assess the underlying cause such as obstetric trauma, Crohn's disease, cryptoglandular infection, or malignancy. Examination under anesthesia and radiologic assessment are often necessary to define the anatomy of the fistula tract and to evaluate the tissues involved. As the status of

Copyright © The American Society of Colon & Rectal Surgeons, Inc. Unauthorized reproduction of this article is prohibited.

the anal sphincter complex plays an integral role in the choice of repair, assessment of anal sphincter anatomy and function are key steps in the evaluation of patients with RVFs.[22,27,29,167–172] Although not one technique of repair is appropriate for all RVFs, the available evidence can help determine effective treatment strategies. Fibrin glue therapy and the use of a plug are not included in the following guidelines because the success of these interventions has proven prohibitively poor for RVFs.[167,168]

12. Nonoperative management is typically recommended for the initial care of obstetrical rectovaginal fistula and may also be considered for other benign and minimally symptomatic fistulas. Grade of recommendation: weak recommendation based on low-quality evidence, 2C.

In most cases, the initial management of RVFs, especially those of obstetric cause, is nonoperative[22,43] and may include baths, wound care, debridement as needed, antibiotics in cases of infection, and stool-bulking fiber supplements for a period usually of 3 to 6 months.[43] The aim of this approach is to resolve acute inflammation and infection. Furthermore, data from an older meta-analysis by Homsi et al,[169] and more recent studies by Oakley et al[170] and Lo et al,[171] demonstrate that a nonoperative approach under these circumstances may result in healing rates ranging from 52% to 66%. Benign, minimally symptomatic RVFs unrelated to obstetrical injury may also be successfully managed with nonoperative therapy, although follow-up is limited.[170]

13. A draining seton may facilitate resolution of acute inflammation or infection associated with rectovaginal fistulas. Grade of recommendation: strong recommendation based on low-quality evidence, 1C.

A draining seton may be helpful in treating or preventing the formation of an abscess within the rectovaginal septum, particularly in patients with a narrow fistula, a small-diameter vaginal side opening, or multiple tracts.[29,119,167,168] Setons may also provide long-term symptomatic relief for patients who are poor candidates for definitive repair. Patients with an active inflammatory or neoplastic process that requires further treatment before definitive repair may also benefit from seton placement. In patients who are considered candidates for definitive repair, draining setons may relieve acute inflammation, edema, and infection and may improve the likelihood of success of subsequent definitive fistula repair.[119,141,168,172]

14. Endorectal advancement flap with or without sphincteroplasty is the procedure of choice for most patients with a rectovaginal fistula. Grade of recommendation: strong recommendation based on low-quality evidence, 1C.

The success of RVF repair with endorectal advancement flap ranges from 41% to 78% depending on the cause of fistula, operative technique, and definition of fistula healing used.[167,168,173,174] Factors associated with failure include endosonographic and manometric abnormalities of the anal sphincter complex, Crohn's disease, previous pelvic radiation, and recurrent fistula.[22,109,119,175] Although a history of failed attempts at fistula repair increases the risk for endorectal advancement flap failure, success with repeat flaps has been reported in 55% to 93% of patients.[22,125,174] Although a diverting stoma has not been shown to significantly improve the outcomes of patients undergoing endorectal advancement flap for RVF, diversion should be considered on an individual case basis.[109,119,176]

The results of an endorectal advancement flap alone for patients with RVF and fecal incontinence with a known sphincter defect are historically poor. In a retrospective study by Tsang et al[177] that included 52 patients with "simple" obstetrical RVFs who underwent 62 procedures (48% of the patients had varying degrees of fecal incontinence), healing was reported in 11 of 27 patients (41%) who underwent endorectal advancement flap and in 28 of 35 patients (80%) who underwent sphincteroplasty ± levatorplasty. Higher rates of fistula healing (more than 80%) with sphincteroplasty under these circumstances also have been reported by others compared to endorectal advancement flap alone.[22,109,167]

In the setting of a low RVF, an endorectal advancement flap may cause mucosal ectropion. Under these circumstances, an alternative flap harvested from the anoderm and perianal skin instead of the rectum should be considered. This technique, combined with sphincteroplasty, was used by Chew and Rieger[176] in 7 consecutive patients with obstetrical low RVFs and resulted in 100% healing at a mean follow-up of 24 months.

15. Episioproctotomy may be used to repair obstetrical or cryptoglandular rectovaginal fistulas in patients with anal sphincter defects. Grade of recommendation: strong recommendation based on low-quality evidence, 1C.

Episioproctotomy is a transperineal technique to repair RVFs that involves division of various degrees of the anterior anal sphincter complex and rectovaginal septum in patients with anal sphincter defects. This approach has been associated with fistula healing in the range of 78% to 100% of patients and has demonstrated acceptable functional outcomes.[27,173,176,178–181] Episioproctotomy differs from sphincteroplasty in terms of the amount of perineal skin, external anal sphincter, and rectovaginal septum that needs to be divided to reach and repair the RVF. A 2007 report by Hull et al[178] retrospectively reviewed the results of episioproctotomy in 42 patients with mostly obstetrical RVFs associated with significant anterior anal sphincter defects and reported recurrent fistulas in only 11 patients (26%). Although 23 patients (55%) had a stoma at the time of episioproctotomy, fecal diversion was not

Copyright © The American Society of Colon & Rectal Surgeons, Inc. Unauthorized reproduction of this article is prohibited.

significantly associated with outcomes. In a smaller study, Rahman et al[182] reported fistula healing in all 8 patients who underwent episioproctotomy for obstetrical fistulas, and none of the patients reported fecal incontinence, with follow-up ranging from 6 months to 8 years. Hull et al,[179] in another retrospective analysis of 50 patients with obstetrical or cryptoglandular RVFs repaired by episioproctotomy, reported fistula healing in 39 patients (78%) and "rare" postoperative fecal incontinence in 46 patients (92%) with a median follow-up of 49 months. Of the 36 patients (72%) who had a stoma before episioproctotomy, most underwent stoma closure within 3 months of their fistula repair (median, 3.4 mo). Furthermore, of the 25 patients (50%) with preoperative fecal incontinence, only 4 patients (8%) experienced postoperative fecal incontinence. In a cohort of 50 patients who underwent episioproctotomy, El-Gazzaz et al[29] reported 39 patients (78%) who were healed after a mean follow-up of 46 months. In this study, outcomes were determined by telephone interviews and mailed standardized questionnaires. Temporary fecal diversion was performed in 36 of these patients (72%) who had recurrent fistula or subjective extensive scarring.

16. A gracilis muscle or bulbocavernosus (Martius) flap is typically recommended for recurrent or otherwise complex rectovaginal fistula. Grade of recommendation: strong recommendation based on low-quality evidence, 1C.

The use of a gracilis muscle flap for the treatment of recurrent RVF has been mainly reported in small retrospective studies with limited follow-up.[119,183–188] One of the larger series evaluating gracilis muscle flap in this setting, by Pinto et al,[119] demonstrated fistula healing in 19 of 24 patients (79%). Other retrospective studies have reported healing rates ranging from 50% to 92%.[167,184,185,187–190] Two series reported postoperative complication rates, ranging between 28% and 47%, and the most common complications included surgical site infection, thigh numbness, and hematoma.[184,188] Picciariello and colleagues[191] reported on quality of life after graciloplasty and noted that there was an improvement in 36-Item Short-Form Survey scores as well as in sexual function.

The use of a Martius (bulbocavernosus) flap for RVF repair has also been reported in small retrospective studies that included patients with various fistula causes and limited follow-up. Trompetto et al[192] reported on 24 patients with low RVF who underwent Martius flaps. In this study, 42% of patients had fistulas of obstetrical origin, and the overall success rate was 91% at a mean follow-up of 42 months. Pitel and colleagues,[193] in a series of 20 consecutive patients undergoing Martius flaps (70% had fecal diversion), reported minor complications in 3 patients (15%) and healing in 13 patients (65%) at a mean follow-up of 35 months. In a series from Songne et al,[194] which included 14 patients with RVF (6 had Crohn's disease), a diverting ostomy was used in all patients, and healing occurred in 13 patients (93%). In 2 additional studies where the Martius flap was used to treat patients with radiation-related RVFs, healing was observed in 11 of 12 and 13 of 14 patients.[195,196]

Although supporting evidence is lacking, a diverting ostomy is generally recommended as an adjunct to Martius and gracilis muscle flap repairs (fecal diversion has been reported in 63% to 100% of these patients).[170,193,194,197,198] However, Oakley et al[170] retrospectively reviewed the outcomes of 176 patients with RVFs treated at multiple centers and reported an 81% fistula healing rate using a variety of repairs (including 9 Martius flaps). In this study, a nonspecified "low rate" of stoma formation was mainly attributed to fistula repairs being performed by urogynecologists. Another small retrospective study, including 16 women with RVFs treated with Martius flaps, used selective fecal diversion in 38% of patients and reported an overall success rate of 94% at a mean follow-up of 1.5 years.[197] Meanwhile, Milito et al[198] also reported a small series of patients with RVF because of Crohn's disease who underwent Martius flaps without a covering stoma and reported a 100% success rate at a mean follow-up of 18 months.

17. Rectovaginal fistulas that result from colorectal anastomotic complications often require a transabdominal approach for repair. Grade of recommendation: strong recommendation based on low-quality evidence, 1C.

In earlier studies, fistulization of a colorectal anastomosis to the vagina was reported to occur in up to 2.2% of cases[30,199,200]; however, more recent publications report higher rates of RVF after failed anastomoses.[29,201] Under these circumstances, fecal diversion is generally recommended as the initial step to facilitate resolution of the acute inflammation and associated symptoms; however, in selected cases with an immediate or early postoperative RVF, reoperation and repeat colorectal anastomosis may be preferable.[29] Fistula healing with diversion alone has also been reported. In 2005, Kosugi et al[33] reported that 6 of 16 patients (37%) with a RVF from a failed colorectal anastomosis healed with diversion alone. In this retrospective series, patients with persistent fistulas were treated with repeat colorectal anastomosis, endorectal advancement flap, or a transperineal interposition flap.

18. Completion proctectomy with or without colonic pull-through or coloanal anastomosis may be required to treat radiation-related or recurrent complex rectovaginal fistula. Grade of recommendation: weak recommendation based on low-quality evidence, 2C.

Recurrent, complex RVFs and fistulas that develop in the setting of pelvic radiation may be amenable to repair with a muscle flap interposition as described previously[195,196]

Copyright © The American Society of Colon & Rectal Surgeons, Inc. Unauthorized reproduction of this article is prohibited.

or proctectomy with primary or staged coloanal anastomosis.[199] A variation of conventional proctectomy may be used under these circumstances (the sleeve excision technique) that include resection of the rectum proximal to the fistula tract, mucosectomy of the rectum at and distal to the fistula, pull-through of the healthy colon through the remaining muscular tube of the rectum, and creation of a sutured coloanal anastomosis. Nowacki and colleagues[202,203] described this technique in women with RVF secondary to pelvic radiotherapy for cervical cancer and reported healing in 11 of 14 patients (79%) and reported that the functional results were "good" in all of the patients who healed. In a more recent retrospective study by Patsouras et al,[204] this technique was performed in 34 patients and early postoperative complications were reported in 51% of patients and late postoperative complications were reported in 32% of patients. In this study, fistula healing occurred in 75% of patients and 18 of 25 patients (72%) surveyed reported having normal postoperative fecal continence.

In the setting of proctectomy, a primary or staged (ie, Turnbull-Cutait procedure) coloanal anastomosis may be used to restore continuity of the bowel. In a retrospective comparison of 67 patients who underwent an operation for a variety of indications (only 3 patients had RVF), the Turnbull-Cutait procedure resulted in decreased rates of anastomotic leak (3% vs 7%) and pelvic abscess (0% vs 5%) compared to primary coloanal anastomosis, although functional outcomes were similar.[199] In a study by Corte et al[167] of 79 patients with RVF (43% secondary to Crohn's disease), 19 patients underwent resection with primary (n = 8) or delayed (n = 11) coloanal anastomosis, and the overall success rate was 91%. In 2016, Karakayali et al[205] reported on 10 patients with RVF secondary to pelvic radiation who underwent pull-through and straight coloanal anastomosis with diverting loop ileostomy and all patients healed without an anastomotic leak. In this study, the fecal incontinence quality-of-life index and depression, lifestyle, and embarrassment scores improved after surgery, and there were no significant changes in reported continence.

Although many patients with RVF report symptomatic relief after a diverting stoma that leaves the affected rectum in situ, Zhong et al[206] noted significantly improved quality of life after patients underwent proctectomy and diverting stoma (n = 10) compared to stoma alone (n = 16) in the setting of RVF related to pelvic radiation. In this study, the proctectomy group had significantly less tenesmus and anal discharge than the colostomy alone group at 6 and 12 months.

Anorectal Fistula Associated With Crohn's Disease

19. Anorectal fistula associated with Crohn's disease is typically managed with a combination of surgical and medical approaches. Grade of recommendation: strong recommendation based on moderate-quality evidence, 1B.

The management of fistulizing anorectal Crohn's disease typically involves a multidisciplinary approach to control infection and optimize the medical management of the underlying Crohn's disease. Given the evolving evidence supporting the multidisciplinary management of patients with fistulizing Crohn's disease, this practice recommendation, which was not included in the 2016 guidelines, was added to the clinical practice guideline.

The mainstay of medical management of anorectal Crohn's disease is biological therapy.[36,207–210] There are limited data regarding anorectal fistula healing with immunosuppressants such as azathioprine, 6-mercaptopurine, cyclosporine, and tacrolimus.[211,212] Randomized controlled trials have shown initial fistula healing rates of 38% to 55% in patients treated with infliximab,[36] with long-term healing occurring in 39% of patients.[209] Although 2 randomized trials showed no benefit of adalimumab over placebo in this setting,[210,213] a subsequent randomized double-blind trial demonstrated 33% healing in the adalimumab group versus 13% in the placebo group ($p < 0.05$).[214] Evidence supporting the use of certolizumab is less compelling. However, the Pegylated Antibody Fragment Evaluation in Crohn's Disease: Safety and Efficacy trial showed that in 36% of patients, anal fistulas healed after treatment with certolizumab compared with only 17% of patients who were treated with placebo ($p = 0.03$); when the criterion for success was defined as 50% or more closure at 2 consecutive visits ≥3 weeks apart, no difference was found between the 2 groups.[215] In many instances, medical therapy is combined, at least initially, with a draining seton.[207,208,216]

In terms of operative solutions, the decision to perform definitive fistula surgery in selected patients with anorectal Crohn's fistula must be individualized and should consider the severity of symptoms, status of infection, fistula tract anatomy, presence of a stricture, and status of Crohn's disease (especially the presence of proctitis). Following fistula surgery, patients with Crohn's disease require additional interventions for nonhealing wounds or recurrent fistula more commonly than patients with cryptoglandular fistula.[17,172] In patients who do not require drainage, antibiotic therapy alone has been shown to be effective in fistulizing Crohn's disease; treatment with metronidazole and fluoroquinolones has demonstrated improvement in symptoms (at least temporarily) in more than 90% of patients.[217] Despite medical and surgical management, patients with Crohn's disease with severe refractory anorectal fistulizing disease may ultimately require proctectomy and permanent fecal diversion.[218–221]

20. Asymptomatic fistulas in patients with Crohn's disease typically do not require surgical treatment. Grade of recommendation: strong recommendation based on low-quality evidence, 1C.

Copyright © The American Society of Colon & Rectal Surgeons, Inc. Unauthorized reproduction of this article is prohibited.

Patients with Crohn's disease who present with an asymptomatic fistula secondary to Crohn's disease or a cryptoglandular infection without signs of local sepsis do not require surgical intervention as these tracts may remain quiescent for extended periods of time. Under these circumstances, proceeding with surgery and risking postoperative morbidity including nonhealing wounds or incontinence are not typically recommended.[222]

21. Draining setons are typically useful in the multimodality therapy of fistulizing anorectal Crohn's disease and may be used for long-term disease control. Grade of recommendation: strong recommendation based on moderate-quality evidence, 1B.

For anorectal fistulas associated with Crohn's disease, long-term draining setons (destination setons) can successfully resolve inflammation and prevent anorectal sepsis by maintaining the external opening and allowing for drainage.[223–226] However, setons can be associated with persistent seepage, a chronic and bothersome symptom for patients, and recurrent sepsis can occur in more than 20% of patients.[216,227,228] Given the observational and randomized evidence available regarding this topic, this recommendation grade was changed from a 1C grade in the 2016 clinical practice guideline to a 1B grade.

In a retrospective study of 32 consecutive patients treated with infliximab for anorectal Crohn's disease, patients who also underwent seton placement (n = 9) had a lower fistula recurrence rate (44% vs 79%; $p < 0.001$) at 3 months and longer time to recurrence (13.5 vs 3.6 months; $p < 0.001$).[227] A systematic review and meta-analysis of 10 studies, including 4 randomized controlled trials, concluded that anti-TNF therapy in combination with temporary seton placement was likely beneficial for fistula healing.[228] Although a meta-analysis of the 4 randomized controlled trials that compared anti-TNF therapy with placebo showed no difference in complete or partial fistula healing, subgroup analysis of the 2 trials with follow-up of >4 weeks demonstrated increased rates of complete fistula healing (46% vs 13%, $p = 0.003$ and 30% vs 13%, $p = 0.03$).

Multimodal treatment with biologic agents and seton drainage has also been associated with improved fistula healing rates.[229,230] In addition, combination therapy has been shown to be more cost-effective and use fewer overall resources compared to anti-TNF therapy alone.[231] The timing of initiating infliximab therapy, whether within 30 days of seton placement or >30 days after surgery, has not been shown to influence healing rates.[232,233]

The optimal timing of seton removal in patients receiving anti-TNF therapy is also not clear. In the multicenter, randomized controlled A Crohn's Disease Clinical Trial Evaluating Infliximab in a New Long-Term Treatment Regimen in Patients with Fistulizing Crohn's Disease II trial that included 282 patients with anorectal (n = 246), rectovaginal, or enterocutaneous fistula, setons were removed within 2 weeks of starting infliximab induction therapy. At week 14, a response, defined as more than 50% reduction in the number of draining fistulas, was observed in 195 patients (69%), whereas 87 patients (31%) showed no response. Meanwhile, 46% of patients who continued on maintenance therapy showed a response at 54 weeks, and 21% of patients who initially showed no response to induction therapy showed a response at 54 weeks.[234] Although this trial studied patients in whom setons were removed within 2 weeks of infliximab induction, another small prospective study of 21 patients found that 85% of patients had resolution of fistula symptoms at 12 weeks when setons were left in place through the induction phase of infliximab.[208]

22. Symptomatic, simple, low anal fistulas in carefully selected patients with Crohn's disease may be treated by lay-open fistulotomy. Grade of recommendation: weak recommendation based on low-quality evidence, 2C.

Fistulotomy may be safely performed in appropriately selected patients with Crohn's disease with an uncomplicated low fistula (ie, less than 30% involvement of the external anal sphincter) in the absence of proctitis.[235–237] Given the baseline incontinence that may be present in patients with anorectal fistulizing Crohn's disease (from the disease process or as a consequence of previous interventions to treat a fistula) and the likelihood of patients developing additional Crohn's disease–related fistulas in the future, preservation of sphincter muscle and function are usually of paramount concern in this setting[238]; proceeding with fistulotomy requires careful consideration under these circumstances.[239–242] Healing rates after fistulotomy range from 62% to 100%, and 6% to 12% of patients report mild incontinence.[223,224,237] However, some studies report higher rates of postoperative incontinence (up to 50%), especially in patients with active proctitis, underscoring the importance of patient selection.[223] Recognizing the benefits and risks associated with fistulotomy in the setting of Crohn's disease, the grade of this recommendation has been changed from a 1C grade in the 2016 clinical practice guidelines to a 2C grade.

23. Endorectal advancement flaps and the LIFT procedure may be used to treat fistula-in-ano associated with Crohn's disease. Grade of recommendation: strong recommendation based on moderate-quality evidence, 1B.

Patients with Crohn's disease and a fistula, ideally, isolated to a single dominant tract without associated sepsis, anal stenosis, proctitis, or interfering scarring from previous anorectal disease or operations, may be considered for an operative repair. In cases in which localized sepsis is present, a draining seton is typically recommended before surgical intervention to improve the likelihood of successful fistula repair.[217,235,236] In patients without signs of sepsis and with otherwise well-controlled Crohn's disease, the most commonly performed repairs

Copyright © The American Society of Colon & Rectal Surgeons, Inc. Unauthorized reproduction of this article is prohibited.

are endorectal advancement flaps and LIFT. Given the observational evidence regarding the evolving role of endorectal advancement flaps and LIFT in patients with Crohn's disease, this recommendation grade was changed from a 2B grade in the 2016 clinical practice guideline to a 1B grade.

A systematic review including 91 patients with Crohn's disease who underwent endorectal advancement flap reported overall fistula healing in 64% of patients (range, 33%–93%) at a median follow-up of 29 months. Incontinence was reported in 9.4% of patients after flap procedures (range, 0%–29%) and was associated with having had previous surgical repairs.[18,110] Alternatively, the LIFT procedure was evaluated in a prospective study of 15 patients with Crohn's disease with transsphincteric fistulas. In this study, 10 patients (67%) remained healed 12 months after surgery, no patients reported incontinence, and quality of life was significantly improved postoperatively.[243] A subsequent retrospective study of 23 consecutive patients with Crohn's disease with transsphincteric fistulas who underwent LIFT found that 11 patients (48%) healed after a median follow-up of 23 months; in patients who failed LIFT, the median time to failure was 9 months.[244]

24. Patients with uncontrolled symptoms from complex anorectal fistulizing Crohn's disease may require fecal diversion or proctectomy. Grade of recommendation: strong recommendation based on low-quality evidence, 1C.

Patients with severe anorectal fistulizing Crohn's disease who do not respond adequately to medical therapy, local surgical intervention, or long-term seton drainage may consider fecal diversion with or without proctectomy to control anorectal sepsis and improve incontinence symptoms and overall quality of life.[245] Retrospective reviews evaluating diversion under these circumstances demonstrate that 64% to 81% of patients have an initial response to this approach[246]; however, only 26% to 50% of these patients experience sustained remission, whereas the remaining patients develop recurring or persistent refractory proctitis and/or symptoms associated with persistent fistula.[221,245] Overall, 45% to 68% of patients treated with an initial fecal diversion ultimately required a proctectomy to control refractory symptoms.[222,235] Concomitant colonic disease, persistent proctitis or anorectal sepsis, previous temporary fecal diversion, more than 2 previous seton placements, fecal incontinence, and anal canal stenosis are associated with the need for proctectomy and permanent fecal diversion in this setting.[221,246,247] In a meta-analysis of 556 patients undergoing fecal diversion for severe refractory anorectal Crohn's disease, 64% of patients (95% CI, 54.1–72.5) had an early clinical response after fecal diversion.[246] In this study, stoma reversal was attempted in 34.5% of patients and was successful in only 17% of patients (95% CI, 11.8–22.9). Of those who underwent stoma reversal, 26.5% of patients (95% CI, 14.1–44.2) required repeat diversion because of severe clinical relapse. Overall, 42% of patients (95% CI, 32.6–51.2) required proctectomy after undergoing otherwise temporary fecal diversion. No significant difference was found in rates of restoration of bowel continuity when prebiological era (14%) and biological era patients (18%) were compared. In this study, the absence of proctitis was the most consistent factor associated with the restoration of bowel continuity.

25. Local administration of mesenchymal stem cells is a safe and effective treatment for selected patients with refractory anorectal fistulas in the setting of Crohn's disease. Grade of recommendation: weak recommendation based on moderate-quality evidence, 2B.

Several phase I,[248–253] phase II,[252,254,255] and phase III[256] clinical trials demonstrate the safety and efficacy of direct delivery of mesenchymal stem cells (MSCs) for the treatment of medically and surgically refractory fistulizing anorectal Crohn's disease. This evolving approach to fistulizing Crohn's disease is not widely available and was not addressed in the 2016 clinical practice guidelines, but sufficient evidence has since been amassed to warrant inclusion in these updated guidelines.

Despite the heterogeneity across study protocols using allogeneic MSCs[250,253,255,256] or autologous MSCs[250,252,253,257–259] derived from bone marrow[254,257] or adipose tissue[251–253,257,258,260] delivered with[251,252,257] or without[254,260] scaffolding at doses ranging from 20 million to 120 million cells,[251,260,261] the only reported adverse events have been anorectal pain and abscesses.[260,261] Efficacy of this approach has ranged from 50% to 83% at follow-up intervals ranging from 6 months to 1 year.[251,260,261] The largest relevant phase III randomized controlled trial evaluating MSCs included 212 patients who received either placebo or 120 million MSCs and reported equivalent rates of anorectal pain and abscess in the 2 arms of the study (13% vs 11% and 12% vs 13%, respectively). In this trial, study patients had significantly improved fistula healing rates compared to placebo control patients (50% vs 34%; $p = 0.02$) at a 6-month follow-up.[255] A meta-analysis confirmed the superior fistula healing rates with MSC treatment compared to controls.[259] Two prospective studies with patients with at least 1-year (n = 131) or 4-year follow-up (n = 13) reported no recurrence of fistulizing anorectal disease after complete healing after a single injection of MSCs.[261,262] Further clinical trials investigating MSCs in the setting of Crohn's disease are underway. In addition, data are accumulating regarding the use of MSCs in cryptoglandular anorectal fistulas, which suggests MSCs are safe in this setting, but perhaps not quite as effective as in perianal Crohn's disease. However, more trials are needed before recommendations can be made regarding the use of MSCs for cryptoglandular fistulas.[263–267]

Copyright © The American Society of Colon & Rectal Surgeons, Inc. Unauthorized reproduction of this article is prohibited.

REFERENCES

1. Cox SW, Senagore AJ, Luchtefeld MA, Mazier WP. Outcome after incision and drainage with fistulotomy for ischiorectal abscess. *Am Surg.* 1997;63:686–689.
2. Gosselink MP, van Onkelen RS, Schouten WR. The cryptoglandular theory revisited. *Colorectal Dis.* 2015;17:1041–1043.
3. Ommer A, Herold A, Berg E, Fürst A, Schiedeck T, Sailer M. German S3-Guideline: rectovaginal fistula. *Ger Med Sci.* 2012;10:Doc15.
4. Abcarian H. Anorectal infection: abscess-fistula. *Clin Colon Rectal Surg.* 2011;24:14–21.
5. Ramanujam PS, Prasad ML, Abcarian H, Tan AB. Perianal abscesses and fistulas. A study of 1023 patients. *Dis Colon Rectum.* 1984;27:593–597.
6. Read DR, Abcarian H. A prospective survey of 474 patients with anorectal abscess. *Dis Colon Rectum.* 1979;22:566–568.
7. Vasilevsky CA, Gordon PH. The incidence of recurrent abscesses or fistula-in-ano following anorectal suppuration. *Dis Colon Rectum.* 1984;27:126–130.
8. McElwain JW, MacLean MD, Alexander RM, Hoexter B, Guthrie JF. Anorectal prlblems: experience with primary fistulectomy for anorectal abscess, a report of 1,000 cases. *Dis Colon Rectum.* 1975;18:646–649.
9. Wang D, Yang G, Qiu J, et al. Risk factors for anal fistula: a case-control study. *Tech Coloproctol.* 2014;18:635–639.
10. Hämäläinen KP, Sainio AP. Incidence of fistulas after drainage of acute anorectal abscesses. *Dis Colon Rectum.* 1998;41:1357–1361.
11. Hamadani A, Haigh PI, Liu IL, Abbas MA. Who is at risk for developing chronic anal fistula or recurrent anal sepsis after initial perianal abscess? *Dis Colon Rectum.* 2009;52:217–221.
12. Schouten WR, van Vroonhoven TJ. Treatment of anorectal abscess with or without primary fistulectomy. Results of a prospective randomized trial. *Dis Colon Rectum.* 1991;34:60–63.
13. Sözener U, Gedik E, Kessaf Aslar A, et al. Does adjuvant antibiotic treatment after drainage of anorectal abscess prevent development of anal fistulas? A randomized, placebo-controlled, double-blind, multicenter study. *Dis Colon Rectum.* 2011;54:923–929.
14. Hall JF, Bordeianou L, Hyman N, et al. Outcomes after operations for anal fistula: results of a prospective, multicenter, regional study. *Dis Colon Rectum.* 2014;57:1304–1308.
15. Hyman N, O'Brien S, Osler T. Outcomes after fistulotomy: results of a prospective, multicenter regional study. *Dis Colon Rectum.* 2009;52:2022–2027.
16. Parks AG, Gordon PH, Hardcastle JD. A classification of fistula-in-ano. *Br J Surg.* 1976;63:1–12.
17. Fazio VW. Complex anal fistulae. *Gastroenterol Clin North Am.* 1987;16:93–114.
18. Mizrahi N, Wexner SD, Zmora O, et al. Endorectal advancement flap: are there predictors of failure? *Dis Colon Rectum.* 2002;45:1616–1621.
19. Kondylis PD, Shalabi A, Kondylis LA, Reilly JC. Male cryptoglandular fistula surgery outcomes: a retrospective analysis. *Am J Surg.* 2009;197:325–330.
20. Sangwan YP, Rosen L, Riether RD, Stasik JJ, Sheets JA, Khubchandani IT. Is simple fistula-in-ano simple? *Dis Colon Rectum.* 1994;37:885–889.
21. Zmora O, Neufeld D, Ziv Y, et al. Prospective, multicenter evaluation of highly concentrated fibrin glue in the treatment of complex cryptogenic perianal fistulas. *Dis Colon Rectum.* 2005;48:2167–2172.
22. Lowry AC, Thorson AG, Rothenberger DA, Goldberg SM. Repair of simple rectovaginal fistulas. Influence of previous repairs. *Dis Colon Rectum.* 1988;31:676–678.
23. Schwartz DA, Loftus EV Jr, Tremaine WJ, et al. The natural history of fistulizing Crohn's disease in Olmsted County, Minnesota. *Gastroenterology.* 2002;122:875–880.
24. Harper PH, Fazio VW, Lavery IC, et al. The long-term outcome in Crohn's disease. *Dis Colon Rectum.* 1987;30:174–179.
25. Wiese DM, Schwartz DA. Managing perianal Crohn's disease. *Curr Gastroenterol Rep.* 2012;14:153–161.
26. Sordo-Mejia R, Gaertner WB. Multidisciplinary and evidence-based management of fistulizing perianal Crohn's disease. *World J Gastrointest Pathophysiol.* 2014;5:239–251.
27. Tozer PJ, Balmforth D, Kayani B, Rahbour G, Hart AL, Phillips RK. Surgical management of rectovaginal fistula in a tertiary referral centre: many techniques are needed. *Colorectal Dis.* 2013;15:871–877.
28. Mazier WP, Senagore AJ, Schiesel EC. Operative repair of anovaginal and rectovaginal fistulas. *Dis Colon Rectum.* 1995;38:4–6.
29. El-Gazzaz G, Hull TL, Mignanelli E, Hammel J, Gurland B, Zutshi M. Obstetric and cryptoglandular rectovaginal fistulas: long-term surgical outcome; quality of life; and sexual function. *J Gastrointest Surg.* 2010;14:1758–1763.
30. Hamilton S, Spencer C, Evans A. Vagino-rectal fistula caused by Bartholin's abscess. *J Obstet Gynaecol.* 2007;27:325–326.
31. Radcliffe AG, Ritchie JK, Hawley PR, Lennard-Jones JE, Northover JM. Anovaginal and rectovaginal fistulas in Crohn's disease. *Dis Colon Rectum.* 1988;31:94–99.
32. Matthiessen P, Hansson L, Sjödahl R, Rutegård J. Anastomotic-vaginal fistula (AVF) after anterior resection of the rectum for cancer–occurrence and risk factors. *Colorectal Dis.* 2010;12:351–357.
33. Kosugi C, Saito N, Kimata Y, et al. Rectovaginal fistulas after rectal cancer surgery: incidence and operative repair by gluteal-fold flap repair. *Surgery.* 2005;137:329–336.
34. Naldini G. Serious unconventional complications of surgery with stapler for haemorrhoidal prolapse and obstructed defaecation because of rectocoele and rectal intussusception. *Colorectal Dis.* 2011;13:323–327.
35. Kasibhatla M, Clough RW, Montana GS, et al. Predictors of severe gastrointestinal toxicity after external beam radiotherapy and interstitial brachytherapy for advanced or recurrent gynecologic malignancies. *Int J Radiat Oncol Biol Phys.* 2006;65:398–403.
36. Present DH, Rutgeerts P, Targan S, et al. Infliximab for the treatment of fistulas in patients with Crohn's disease. *N Engl J Med.* 1999;340:1398–1405.
37. Vogel JD, Johnson EK, Morris AM, et al. Clinical practice guideline for the management of anorectal abscess, fistula-in-ano, and rectovaginal fistula. *Dis Colon Rectum.* 2016;59:1117–1133.
38. Guyatt G, Gutterman D, Baumann MH, et al. Grading strength of recommendations and quality of evidence in clinical guidelines: report from an american college of chest physicians task force. *Chest.* 2006;129:174–181.

Copyright © The American Society of Colon & Rectal Surgeons, Inc. Unauthorized reproduction of this article is prohibited.

39. Chrabot CM, Prasad ML, Abcarian H. Recurrent anorectal abscesses. *Dis Colon Rectum.* 1983;26:105–108.
40. Held D, Khubchandani I, Sheets J, Stasik J, Rosen L, Riether R. Management of anorectal horseshoe abscess and fistula. *Dis Colon Rectum.* 1986;29:793–797.
41. Herr CH, Williams JC. Supralevator anorectal abscess presenting as acute low back pain and sciatica. *Ann Emerg Med.* 1994;23:132–135.
42. Sneider EB, Maykel JA. Anal abscess and fistula. *Gastroenterol Clin North Am.* 2013;42:773–784.
43. Klein JW. Common anal problems. *Med Clin North Am.* 2014;98:609–623.
44. Beck DE, Wexner SD, Rafferty JF. *Gordon and Nivatvongs' Principles and Practice of Surgery for the Colon, Rectum, and Anus*. 4th ed. New York, NY: Thieme Medical Publishers, Inc; 2019.
45. Cirocco WC, Reilly JC. Challenging the predictive accuracy of Goodsall's rule for anal fistulas. *Dis Colon Rectum.* 1992;35:537–542.
46. Gonzalez-Ruiz C, Kaiser AM, Vukasin P, Beart RW Jr, Ortega AE. Intraoperative physical diagnosis in the management of anal fistula. *Am Surg.* 2006;72:11–15.
47. Gunawardhana PA, Deen KI. Comparison of hydrogen peroxide instillation with Goodsall's rule for fistula-in-ano. *ANZ J Surg.* 2001;71:472–474.
48. Caliste X, Nazir S, Goode T, et al. Sensitivity of computed tomography in detection of perirectal abscess. *Am Surg.* 2011;77:166–168.
49. Makowiec F, Laniado M, Jehle EC, Claussen CD, Starlinger M. Magnetic resonance imaging in perianal Crohn's disease. *Inflamm Bowel Dis.* 1995;1:256–265.
50. Singh K, Singh N, Thukral C, Singh KP, Bhalla V. Magnetic resonance imaging (MRI) evaluation of perianal fistulae with surgical correlation. *J Clin Diagn Res.* 2014;8:RC01–RC04.
51. Konan A, Onur MR, Özmen MN. The contribution of preoperative MRI to the surgical management of anal fistulas. *Diagn Interv Radiol.* 2018;24:321–327.
52. Brillantino A, Iacobellis F, Reginelli A, et al. Preoperative assessment of simple and complex anorectal fistulas: tridimensional endoanal ultrasound? Magnetic resonance? Both? *Radiol Med.* 2019;124:339–349.
53. Weisman N, Abbas MA. Prognostic value of endoanal ultrasound for fistula-in-ano: a retrospective analysis. *Dis Colon Rectum.* 2008;51:1089–1092.
54. Poen AC, Felt-Bersma RJ, Eijsbouts QA, Cuesta MA, Meuwissen SG. Hydrogen peroxide-enhanced transanal ultrasound in the assessment of fistula-in-ano. *Dis Colon Rectum.* 1998;41:1147–1152.
55. Emile SH, Magdy A, Youssef M, et al. Utility of endoanal ultrasonography in assessment of primary and recurrent anal fistulas and for detection of associated anal sphincter defects. *J Gastrointest Surg.* 2017;21:1879–1887.
56. Tantiphlachiva K, Sahakitrungruang C, Pattanaarun J, Rojanasakul A. Effects of preoperative endoanal ultrasound on functional outcome after anal fistula surgery. *BMJ Open Gastroenterol.* 2019;6:e000279.
57. Schwartz DA, Wiersema MJ, Dudiak KM, et al. A comparison of endoscopic ultrasound, magnetic resonance imaging, and exam under anesthesia for evaluation of Crohn's perianal fistulas. *Gastroenterology.* 2001;121:1064–1072.
58. Plaikner M, Loizides A, Peer S, et al. Transperineal ultrasonography as a complementary diagnostic tool in identifying acute perianal sepsis. *Tech Coloproctol.* 2014;18:165–171.
59. Maconi G, Ardizzone S, Greco S, Radice E, Bezzio C, Bianchi Porro G. Transperineal ultrasound in the detection of perianal and rectovaginal fistulae in Crohn's disease. *Am J Gastroenterol.* 2007;102:2214–2219.
60. Maconi G, Tonolini M, Monteleone M, et al. Transperineal perineal ultrasound versus magnetic resonance imaging in the assessment of perianal Crohn's disease. *Inflamm Bowel Dis.* 2013;19:2737–2743.
61. Nevler A, Beer-Gabel M, Lebedyev A, et al. Transperineal ultrasonography in perianal Crohn's disease and recurrent cryptogenic fistula-in-ano. *Colorectal Dis.* 2013;15:1011–1018.
62. Bor R, Farkas K, Bálint A, et al. Prospective comparison of magnetic resonance imaging, transrectal and transperineal sonography, and surgical findings in complicated perianal Crohn disease. *J Ultrasound Med.* 2016;35:2367–2372.
63. Beck DE, Fazio VW, Lavery IC, Jagelman DG, Weakley FL. Catheter drainage of ischiorectal abscesses. *South Med J.* 1988;81:444–446.
64. Alder AC, Thornton J, McHard K, Buckins L, Barber R, Skinner MA. A comparison of traditional incision and drainage versus catheter drainage of soft tissue abscesses in children. *J Pediatr Surg.* 2011;46:1942–1947.
65. Isbister WH. A simple method for the management of anorectal abscess. *Aust N Z J Surg.* 1987;57:771–774.
66. Ladd AP, Levy MS, Quilty J. Minimally invasive technique in treatment of complex, subcutaneous abscesses in children. *J Pediatr Surg.* 2010;45:1562–1566.
67. Ho YH, Tan M, Chui CH, Leong A, Eu KW, Seow-Choen F. Randomized controlled trial of primary fistulotomy with drainage alone for perianal abscesses. *Dis Colon Rectum.* 1997;40:1435–1438.
68. Zhu DA, Houlihan LM, Mohan HM, McCourt M, Andrews E. Packing versus mushroom catheters following incision and drainage in anorectal abscess. *Ir J Med Sci.* 2019;188:1343–1348.
69. Millan M, García-Granero E, Esclápez P, Flor-Lorente B, Espí A, Lledó S. Management of intersphincteric abscesses. *Colorectal Dis.* 2006;8:777–780.
70. Hanley PH, Ray JE, Pennington EE, Grablowsky OM. Fistula-in-ano: a ten-year follow-up study of horseshoe-abscess fistula-in-ano. *Dis Colon Rectum.* 1976;19:507–515.
71. Hanley PH. Conservative surgical correction of horseshoe abscess and fistula. *Dis Colon Rectum.* 1965;8:364–368.
72. Browder LK, Sweet S, Kaiser AM. Modified Hanley procedure for management of complex horseshoe fistulae. *Tech Coloproctol.* 2009;13:301–306.
73. Ustynoski K, Rosen L, Stasik J, Riether R, Sheets J, Khubchandani IT. Horseshoe abscess fistula. Seton treatment. *Dis Colon Rectum.* 1990;33:602–605.
74. Bokhari S, Lindsey I. Incontinence following sphincter division for treatment of anal fistula. *Colorectal Dis.* 2010;12:e135–e139.
75. Malik AI, Nelson RL, Tou S. Incision and drainage of perianal abscess with or without treatment of anal fistula. *Cochrane Database Syst Rev.* 2010;(7):CD006827.
76. Wang C, Rosen L. Management of low transsphincteric anal fistula with serial setons and interval muscle-cutting fistulotomy. *J Integr Med.* 2016;14:154–158.

Copyright © The American Society of Colon & Rectal Surgeons, Inc. Unauthorized reproduction of this article is prohibited.

77. Oliver I, Lacueva FJ, Pérez Vicente F, et al. Randomized clinical trial comparing simple drainage of anorectal abscess with and without fistula track treatment. *Int J Colorectal Dis.* 2003;18:107–110.
78. Llera JL, Levy RC. Treatment of cutaneous abscess: a double-blind clinical study. *Ann Emerg Med.* 1985;14:15–19.
79. López J, Gómez G, Rodriguez K, Dávila J, Núñez J, Anaya L. Comparative study of drainage and antibiotics versus drainage only in the management of primary subcutaneous abscesses. *Surg Infect (Larchmt).* 2018;19:345–351.
80. Seow-En I, Ngu J. Routine operative swab cultures and postoperative antibiotic use for uncomplicated perianal abscesses are unnecessary. *ANZ J Surg.* 2017;87:356–359.
81. Ghahramani L, Minaie MR, Arasteh P, et al. Antibiotic therapy for prevention of fistula in-ano after incision and drainage of simple perianal abscess: a randomized single blind clinical trial. *Surgery.* 2017;162:1017–1025.
82. Albright JB, Pidala MJ, Cali JR, Snyder MJ, Voloyiannis T, Bailey HR. MRSA-related perianal abscesses: an underrecognized disease entity. *Dis Colon Rectum.* 2007;50:996–1003.
83. Brown SR, Horton JD, Davis KG. Perirectal abscess infections related to MRSA: a prevalent and underrecognized pathogen. *J Surg Educ.* 2009;66:264–266.
84. Stevens DL, Bisno AL, Chambers HF, et al. Practice guidelines for the diagnosis and management of skin and soft tissue infections: 2014 update by the Infectious Diseases Society of America. *Clin Infect Dis.* 2014;59:147–159.
85. Goldberg GS, Orkin BA, Smith LE. Microbiology of human immunodeficiency virus anorectal disease. *Dis Colon Rectum.* 1994;37:439–443.
86. Glenn J, Cotton D, Wesley R, Pizzo P. Anorectal infections in patients with malignant diseases. *Rev Infect Dis.* 1988;10: 42–52.
87. Grewal H, Guillem JG, Quan SH, Enker WE, Cohen AM. Anorectal disease in neutropenic leukemic patients. Operative vs. nonoperative management. *Dis Colon Rectum.* 1994;37:1095–1099.
88. Sullivan PS, Moreno C. A multidisciplinary approach to perianal and intra-abdominal infections in the neutropenic cancer patient. *Oncology (Williston Park).* 2015;29: 581–590.
89. Badgwell BD, Chang GJ, Rodriguez-Bigas MA, et al. Management and outcomes of anorectal infection in the cancer patient. *Ann Surg Oncol.* 2009;16:2752–2758.
90. Büyükaşik Y, Ozcebe OI, Sayinalp N, et al. Perianal infections in patients with leukemia: importance of the course of neutrophil count. *Dis Colon Rectum.* 1998;41:81–85.
91. Abramowitz L, Soudan D, Souffran M, et al; Groupe de Recherche en Proctologie de la Société Nationale Française de Colo-Proctologie and the Club de Réflexion des Cabinets et Groupe d'Hépato-Gastroentérologie. The outcome of fistulotomy for anal fistula at 1 year: a prospective multicentre French study. *Colorectal Dis.* 2016;18:279–285.
92. Litta F, Parello A, De Simone V, Grossi U, Orefice R, Ratto C. Fistulotomy and primary sphincteroplasty for anal fistula: long-term data on continence and patient satisfaction. *Tech Coloproctol.* 2019;23:993–1001.
93. Garcia-Aguilar J, Belmonte C, Wong WD, Goldberg SM, Madoff RD. Anal fistula surgery. Factors associated with recurrence and incontinence. *Dis Colon Rectum.* 1996;39:723–729.
94. Davies M, Harris D, Lohana P, et al. The surgical management of fistula-in-ano in a specialist colorectal unit. *Int J Colorectal Dis.* 2008;23:833–838.
95. Göttgens KW, Janssen PT, Heemskerk J, et al. Long-term outcome of low perianal fistulas treated by fistulotomy: a multicenter study. *Int J Colorectal Dis.* 2015;30:213–219.
96. van Tets WF, Kuijpers HC. Continence disorders after anal fistulotomy. *Dis Colon Rectum.* 1994;37:1194–1197.
97. Jordán J, Roig JV, García-Armengol J, García-Granero E, Solana A, Lledó S. Risk factors for recurrence and incontinence after anal fistula surgery. *Colorectal Dis.* 2010;12:254–260.
98. Ho YH, Tan M, Leong AF, Seow-Choen F. Marsupialization of fistulotomy wounds improves healing: a randomized controlled trial. *Br J Surg.* 1998;85:105–107.
99. Pescatori M, Ayabaca SM, Cafaro D, Iannello A, Magrini S. Marsupialization of fistulotomy and fistulectomy wounds improves healing and decreases bleeding: a randomized controlled trial. *Colorectal Dis.* 2006;8:11–14.
100. Jain BK, Vaibhaw K, Garg PK, Gupta S, Mohanty D. Comparison of a fistulectomy and a fistulotomy with marsupialization in the management of a simple anal fistula: a randomized, controlled pilot trial. *J Korean Soc Coloproctol.* 2012;28:78–82.
101. Anan M, Emile SH, Elgendy H, et al. Fistulotomy with or without marsupialisation of wound edges in treatment of simple anal fistula: a randomised controlled trial. *Ann R Coll Surg Engl.* 2019;101:472–478.
102. Alvandipour M, Ala S, Tavakoli H, Yazdani Charati J, Shiva A. Efficacy of 10% sucralfate ointment after anal fistulotomy: a prospective, double-blind, randomized, placebo-controlled trial. *Int J Surg.* 2016;36:13–17.
103. Sanad A, Emile S, Thabet W, Ellaithy R. A randomized controlled trial on the effect of topical phenytoin 2% on wound healing after anal fistulotomy. *Colorectal Dis.* 2019;21: 697–704.
104. Kronborg O. To lay open or excise a fistula-in-ano: a randomized trial. *Br J Surg.* 1985;72:970.
105. Xu Y, Liang S, Tang W. Meta-analysis of randomized clinical trials comparing fistulectomy versus fistulotomy for low anal fistula. *Springerplus.* 2016;5:1722.
106. Jarrar A, Church J. Advancement flap repair: a good option for complex anorectal fistulas. *Dis Colon Rectum.* 2011;54:1537–1541.
107. Mitalas LE, Dwarkasing RS, Verhaaren R, Zimmerman DD, Schouten WR. Is the outcome of transanal advancement flap repair affected by the complexity of high transsphincteric fistulas? *Dis Colon Rectum.* 2011;54:857–862.
108. Madbouly KM, El Shazly W, Abbas KS, Hussein AM. Ligation of intersphincteric fistula tract versus mucosal advancement flap in patients with high transsphincteric fistula-in-ano: a prospective randomized trial. *Dis Colon Rectum.* 2014;57:1202–1208.
109. Sonoda T, Hull T, Piedmonte MR, Fazio VW. Outcomes of primary repair of anorectal and rectovaginal fistulas using the endorectal advancement flap. *Dis Colon Rectum.* 2002;45:1622–1628.
110. Soltani A, Kaiser AM. Endorectal advancement flap for cryptoglandular or Crohn's fistula-in-ano. *Dis Colon Rectum.* 2010;53:486–495.
111. Podetta M, Scarpa CR, Zufferey G, et al. Mucosal advancement flap for recurrent complex anal fistula: a repeatable procedure. *Int J Colorectal Dis.* 2019;34:197–200.

Copyright © The American Society of Colon & Rectal Surgeons, Inc. Unauthorized reproduction of this article is prohibited.

112. Wright M, Thorson A, Blatchford G, et al. What happens after a failed LIFT for anal fistula? *Am J Surg.* 2017;214:1210–1213.
113. Goos M, Manegold P, Grüneberger M, Thomusch O, Ruf G. Long-term results after endoanal advancement flap repair for fistulas-in-ano. How important is the aetiology? *Int J Colorectal Dis.* 2015;30:413–419.
114. Jones IT, Fazio VW, Jagelman DG. The use of transanal rectal advancement flaps in the management of fistulas involving the anorectum. *Dis Colon Rectum.* 1987;30:919–923.
115. Schouten WR, Zimmerman DD, Briel JW. Transanal advancement flap repair of transsphincteric fistulas. *Dis Colon Rectum.* 1999;42:1419–1422.
116. Schwandner O. Obesity is a negative predictor of success after surgery for complex anal fistula. *BMC Gastroenterol.* 2011;11:61.
117. Zimmerman DD, Briel JW, Gosselink MP, Schouten WR. Anocutaneous advancement flap repair of transsphincteric fistulas. *Dis Colon Rectum.* 2001;44:1474–1480.
118. Boenicke L, Karsten E, Zirngibl H, Ambe P. Advancement flap for treatment of complex cryptoglandular anal fistula: prediction of therapy success or failure using anamnestic and clinical parameters. *World J Surg.* 2017;41:2395–2400.
119. Pinto RA, Peterson TV, Shawki S, Davila GW, Wexner SD. Are there predictors of outcome following rectovaginal fistula repair? *Dis Colon Rectum.* 2010;53:1240–1247.
120. Balciscueta Z, Uribe N, Balciscueta I, Andreu-Ballester JC, García-Granero E. Rectal advancement flap for the treatment of complex cryptoglandular anal fistulas: a systematic review and meta-analysis. *Int J Colorectal Dis.* 2017;32:599–609.
121. Balciscueta Z, Uribe N, Mínguez M, García-Granero E. The changes in resting anal pressure after performing full-thickness rectal advancement flaps. *Am J Surg.* 2017;214:428–431.
122. Rojanasakul A, Pattanaarun J, Sahakitrungruang C, Tantiphlachiva K. Total anal sphincter saving technique for fistula-in-ano; the ligation of intersphincteric fistula tract. *J Med Assoc Thai.* 2007;90:581–586.
123. Hong KD, Kang S, Kalaskar S, Wexner SD. Ligation of intersphincteric fistula tract (LIFT) to treat anal fistula: systematic review and meta-analysis. *Tech Coloproctol.* 2014;18:685–691.
124. Emile SH, Khan SM, Adejumo A, Koroye O. Ligation of intersphincteric fistula tract (LIFT) in treatment of anal fistula: an updated systematic review, meta-analysis, and meta-regression of the predictors of failure. *Surgery.* 2020;167:484–492.
125. Sirany AM, Nygaard RM, Morken JJ. The ligation of the intersphincteric fistula tract procedure for anal fistula: a mixed bag of results. *Dis Colon Rectum.* 2015;58:604–612.
126. Alasari S, Kim NK. Overview of anal fistula and systematic review of ligation of the intersphincteric fistula tract (LIFT). *Tech Coloproctol.* 2014;18:13–22.
127. Vergara-Fernandez O, Espino-Urbina LA. Ligation of intersphincteric fistula tract: what is the evidence in a review? *World J Gastroenterol.* 2013;19:6805–6813.
128. Zirak-Schmidt S, Perdawood SK. Management of anal fistula by ligation of the intersphincteric fistula tract—a systematic review. *Dan Med J.* 2014;61:A4977.
129. Malakorn S, Sammour T, Khomvilai S, et al. Ligation of intersphincteric fistula tract for fistula in ano: lessons learned from a decade of experience. *Dis Colon Rectum.* 2017;60:1065–1070.
130. Han JG, Wang ZJ, Zheng Y, et al. Ligation of intersphincteric fistula tract vs ligation of the intersphincteric fistula tract plus a bioprosthetic anal fistula plug procedure in patients with transsphincteric anal fistula: early results of a multicenter prospective randomized trial. *Ann Surg.* 2016;264:917–922.
131. Tyler KM, Aarons CB, Sentovich SM. Successful sphincter-sparing surgery for all anal fistulas. *Dis Colon Rectum.* 2007;50:1535–1539.
132. van der Hagen SJ, Baeten CG, Soeters PB, van Gemert WG. Staged mucosal advancement flap versus staged fibrin sealant in the treatment of complex perianal fistulas. *Gastroenterol Res Pract.* 2011;2011:186350.
133. Wanitsuwan W, Junmitsakul K, Jearanai S, Lohsiriwat V. Video-assisted ligation of intersphincteric fistula tract for complex anal fistula: technique and preliminary outcomes. *Dis Colon Rectum.* 2020;63:1534–1540.
134. Zwiep TM, Gilbert R, Boushey RP, et al. Comparison of ligation of the intersphincteric fistula tract and BioLIFT for the treatment of transsphincteric anal fistula: a retrospective analysis. *Dis Colon Rectum.* 2020;63:365–370.
135. Williams JG, MacLeod CA, Rothenberger DA, Goldberg SM. Seton treatment of high anal fistulae. *Br J Surg.* 1991;78:1159–1161.
136. Rosen DR, Kaiser AM. Definitive seton management for transsphincteric fistula-in-ano: harm or charm? *Colorectal Dis.* 2016;18:488–495.
137. Patton V, Chen CM, Lubowski D. Long-term results of the cutting seton for high anal fistula. *ANZ J Surg.* 2015;85:720–727.
138. Ritchie RD, Sackier JM, Hodde JP. Incontinence rates after cutting seton treatment for anal fistula. *Colorectal Dis.* 2009;11:564–571.
139. Adamina M, Hoch JS, Burnstein MJ. To plug or not to plug: a cost-effectiveness analysis for complex anal fistula. *Surgery.* 2010;147:72–78.
140. Christoforidis D, Pieh MC, Madoff RD, Mellgren AF. Treatment of transsphincteric anal fistulas by endorectal advancement flap or collagen fistula plug: a comparative study. *Dis Colon Rectum.* 2009;52:18–22.
141. El-Gazzaz G, Zutshi M, Hull T. A retrospective review of chronic anal fistulae treated by anal fistulae plug. *Colorectal Dis.* 2010;12:442–447.
142. Kleif J, Hagen K, Wille-Jørgensen P. Acceptable results using plug for the treatment of complex anal fistulas. *Dan Med Bull.* 2011;58:A4254.
143. Safar B, Jobanputra S, Sands D, Weiss EG, Nogueras JJ, Wexner SD. Anal fistula plug: initial experience and outcomes. *Dis Colon Rectum.* 2009;52:248–252.
144. Herold A, Ommer A, Fürst A, et al. Results of the Gore Bio-A fistula plug implantation in the treatment of anal fistula: a multicentre study. *Tech Coloproctol.* 2016;20:585–590.
145. Bondi J, Avdagic J, Karlbom U, et al. Randomized clinical trial comparing collagen plug and advancement flap for transsphincteric anal fistula. *Br J Surg.* 2017;104:1160–1166.
146. Kontovounisios C, Tekkis P, Tan E, Rasheed S, Darzi A, Wexner SD. Adoption and success rates of perineal procedures for fistula-in-ano: a systematic review. *Colorectal Dis.* 2016;18:441–458.
147. Ellis CN. Bioprosthetic plugs for complex anal fistulas: an early experience. *J Surg Educ.* 2007;64:36–40.

Copyright © The American Society of Colon & Rectal Surgeons, Inc. Unauthorized reproduction of this article is prohibited.

148. Senéjoux A, Siproudhis L, Abramowitz L, et al; Groupe d'Etude Thérapeutique des Affections Inflammatoires du tube Digestif [GETAID]. Fistula plug in fistulising ano-perineal Crohn's disease: a randomised controlled trial. *J Crohns Colitis.* 2016;10:141–148.
149. Adams T, Yang J, Kondylis LA, Kondylis PD. Long-term outlook after successful fibrin glue ablation of cryptoglandular transsphincteric fistula-in-ano. *Dis Colon Rectum.* 2008;51:1488–1490.
150. Sentovich SM. Fibrin glue for anal fistulas: long-term results. *Dis Colon Rectum.* 2003;46:498–502.
151. Swinscoe MT, Ventakasubramaniam AK, Jayne DG. Fibrin glue for fistula-in-ano: the evidence reviewed. *Tech Coloproctol.* 2005;9:89–94.
152. Yeung JM, Simpson JA, Tang SW, Armitage NC, Maxwell-Armstrong C. Fibrin glue for the treatment of fistulae in ano—a method worth sticking to? *Colorectal Dis.* 2010;12:363–366.
153. Buchanan GN, Bartram CI, Phillips RK, et al. Efficacy of fibrin sealant in the management of complex anal fistula: a prospective trial. *Dis Colon Rectum.* 2003;46:1167–1174.
154. Lindsey I, Smilgin-Humphreys MM, Cunningham C, Mortensen NJ, George BD. A randomized, controlled trial of fibrin glue vs. conventional treatment for anal fistula. *Dis Colon Rectum.* 2002;45:1608–1615.
155. Loungnarath R, Dietz DW, Mutch MG, Birnbaum EH, Kodner IJ, Fleshman JW. Fibrin glue treatment of complex anal fistulas has low success rate. *Dis Colon Rectum.* 2004;47:432–436.
156. Cintron JR, Park JJ, Orsay CP, et al. Repair of fistulas-in-ano using fibrin adhesive: long-term follow-up. *Dis Colon Rectum.* 2000;43:944–949.
157. Altomare DF, Greco VJ, Tricomi N, et al. Seton or glue for trans-sphincteric anal fistulae: a prospective randomized crossover clinical trial. *Colorectal Dis.* 2011;13:82–86.
158. de la Portilla F, Muñoz-Cruzado MVD, Maestre MV, et al. Platelet-rich plasma (PRP) versus fibrin glue in cryptogenic fistula-in-ano: a phase III single-center, randomized, double-blind trial. *Int J Colorectal Dis.* 2019;34:1113–1119.
159. Sugrue J, Mantilla N, Abcarian A, et al. Sphincter-sparing anal fistula repair: are we getting better? *Dis Colon Rectum.* 2017;60:1071–1077.
160. Jiang HH, Liu HL, Li Z, et al. Video-assisted anal fistula treatment (VAAFT) for complex anal fistula: a preliminary evaluation in China. *Med Sci Monit.* 2017;23:2065–2071.
161. Seow-En I, Seow-Choen F, Koh PK. An experience with video-assisted anal fistula treatment (VAAFT) with new insights into the treatment of anal fistulae. *Tech Coloproctol.* 2016;20:389–393.
162. Schwandner O. Video-assisted anal fistula treatment (VAAFT) combined with advancement flap repair in Crohn's disease. *Tech Coloproctol.* 2013;17:221–225.
163. Meinero P, Mori L. Video-assisted anal fistula treatment (VAAFT): a novel sphincter-saving procedure for treating complex anal fistulas. *Tech Coloproctol.* 2011;15:417–422.
164. Elfeki H, Shalaby M, Emile SH, Sakr A, Mikael M, Lundby L. A systematic review and meta-analysis of the safety and efficacy of fistula laser closure. *Tech Coloproctol.* 2020;24:265–274.
165. Prosst RL, Joos AK, Ehni W, Bussen D, Herold A. Prospective pilot study of anorectal fistula closure with the OTSC Proctology. *Colorectal Dis.* 2015;17:81–86.
166. Prosst RL, Joos AK. Short-term outcomes of a novel endoscopic clipping device for closure of the internal opening in 100 anorectal fistulas. *Tech Coloproctol.* 2016;20:753–758.
167. Corte H, Maggiori L, Treton X, Lefevre JH, Ferron M, Panis Y. Rectovaginal fistula: what is the optimal strategy?: An analysis of 79 patients undergoing 286 procedures. *Ann Surg.* 2015;262:855–860.
168. de Parades V, Far HS, Etienney I, Zeitoun JD, Atienza P, Bauer P. Seton drainage and fibrin glue injection for complex anal fistulas. *Colorectal Dis.* 2010;12:459–463.
169. Homsi R, Daikoku NH, Littlejohn J, Wheeless CR Jr. Episiotomy: risks of dehiscence and rectovaginal fistula. *Obstet Gynecol Surv.* 1994;49:803–808.
170. Oakley SH, Brown HW, Yurteri-Kaplan L, et al. Practice patterns regarding management of rectovaginal fistulae: a multicenter review from the fellows' pelvic research network. *Female Pelvic Med Reconstr Surg.* 2015;21:123–128.
171. Lo TS, Huang YH, Dass AK, Karim N, Uy-Patrimonio MC. Rectovaginal fistula: twenty years of rectovaginal repair. *J Obstet Gynaecol Res.* 2016;42:1361–1368.
172. O'Leary DP, Milroy CE, Durdey P. Definitive repair of anovaginal fistula in Crohn's disease. *Ann R Coll Surg Engl.* 1998;80:250–252.
173. MacRae HM, McLeod RS, Cohen Z, Stern H, Reznick R. Treatment of rectovaginal fistulas that has failed previous repair attempts. *Dis Colon Rectum.* 1995;38:921–925.
174. Halverson AL, Hull TL, Fazio VW, Church J, Hammel J, Floruta C. Repair of recurrent rectovaginal fistulas. *Surgery.* 2001;130:753–757.
175. Baig MK, Zhao RH, Yuen CH, et al. Simple rectovaginal fistulas. *Int J Colorectal Dis.* 2000;15:323–327.
176. Chew SS, Rieger NA. Transperineal repair of obstetric-related anovaginal fistula. *Aust N Z J Obstet Gynaecol.* 2004;44:68–71.
177. Tsang CB, Madoff RD, Wong WD, et al. Anal sphincter integrity and function influences outcome in rectovaginal fistula repair. *Dis Colon Rectum.* 1998;41:1141–1146.
178. Hull TL, Bartus C, Bast J, Floruta C, Lopez R. Multimedia article. Success of episioproctotomy for cloaca and rectovaginal fistula. *Dis Colon Rectum.* 2007;50:97–101.
179. Hull TL, El-Gazzaz G, Gurland B, Church J, Zutshi M. Surgeons should not hesitate to perform episioproctotomy for rectovaginal fistula secondary to cryptoglandular or obstetrical origin. *Dis Colon Rectum.* 2011;54:54–59.
180. Khanduja KS, Padmanabhan A, Kerner BA, Wise WE, Aguilar PS. Reconstruction of rectovaginal fistula with sphincter disruption by combining rectal mucosal advancement flap and anal sphincteroplasty. *Dis Colon Rectum.* 1999;42:1432–1437.
181. Soriano D, Lemoine A, Laplace C, et al. Results of recto-vaginal fistula repair: retrospective analysis of 48 cases. *Eur J Obstet Gynecol Reprod Biol.* 2001;96:75–79.
182. Rahman MS, Al-Suleiman SA, El-Yahia AR, Rahman J. Surgical treatment of rectovaginal fistula of obstetric origin: a review of 15 years' experience in a teaching hospital. *J Obstet Gynaecol.* 2003;23:607–610.
183. Zmora O, Tulchinsky H, Gur E, Goldman G, Klausner JM, Rabau M. Gracilis muscle transposition for fistulas between the rectum and urethra or vagina. *Dis Colon Rectum.* 2006;49:1316–1321.

Copyright © The American Society of Colon & Rectal Surgeons, Inc. Unauthorized reproduction of this article is prohibited.

184. Korsun S, Liebig-Hoerl G, Fuerst A. Gracilis muscle transposition for treatment of recurrent anovaginal, rectovaginal, rectourethral, and pouch-vaginal fistulas in patients with inflammatory bowel disease. *Tech Coloproctol.* 2019;23:43–52.
185. Ulrich D, Roos J, Jakse G, Pallua N. Gracilis muscle interposition for the treatment of recto-urethral and rectovaginal fistulas: a retrospective analysis of 35 cases. *J Plast Reconstr Aesthet Surg.* 2009;62:352–356.
186. Rottoli M, Vallicelli C, Boschi L, Cipriani R, Poggioli G. Gracilis muscle transposition for the treatment of recurrent rectovaginal and pouch-vaginal fistula: is Crohn's disease a risk factor for failure? A prospective cohort study. *Updates Surg.* 2018;70:485–490.
187. Park SO, Hong KY, Park KJ, Chang H, Shin JY, Jeong SY. Treatment of rectovaginal fistula with gracilis muscle flap transposition: long-term follow-up. *Int J Colorectal Dis.* 2017;32:1029–1032.
188. Wexner SD, Ruiz DE, Genua J, Nogueras JJ, Weiss EG, Zmora O. Gracilis muscle interposition for the treatment of rectourethral, rectovaginal, and pouch-vaginal fistulas: results in 53 patients. *Ann Surg.* 2008;248:39–43.
189. Troja A, Käse P, El-Sourani N, Raab HR, Antolovic D. Treatment of recurrent rectovaginal/pouch-vaginal fistulas by gracilis muscle transposition—a single center experience. *J Visc Surg.* 2013;150:379–382.
190. Nassar OA. Primary repair of rectovaginal fistulas complicating pelvic surgery by gracilis myocutaneous flap. *Gynecol Oncol.* 2011;121:610–614.
191. Picciariello A, Papagni V, De Fazio M, et al. Functional outcome and quality of life evaluation of graciloplasty for the treatment of complex recto-vaginal and recto-urethral fistulas. *Updates Surg.* 2020;72:205–211.
192. Trompetto M, Realis Luc A, Novelli E, Tutino R, Clerico G, Gallo G. Use of the Martius advancement flap for low rectovaginal fistulas. *Colorectal Dis.* 2019;21:1421–1428.
193. Pitel S, Lefevre JH, Parc Y, Chafai N, Shields C, Tiret E. Martius advancement flap for low rectovaginal fistula: short- and long-term results. *Colorectal Dis.* 2011;13:e112–e115.
194. Songne K, Scotté M, Lubrano J, et al. Treatment of anovaginal or rectovaginal fistulas with modified Martius graft. *Colorectal Dis.* 2007;9:653–656.
195. Aartsen EJ, Sindram IS. Repair of the radiation induced rectovaginal fistulas without or with interposition of the bulbocavernosus muscle (Martius procedure). *Eur J Surg Oncol.* 1988;14:171–177.
196. White AJ, Buchsbaum HJ, Blythe JG, Lifshitz S. Use of the bulbocavernosus muscle (Martius procedure) for repair of radiation-induced rectovaginal fistulas. *Obstet Gynecol.* 1982;60:114–118.
197. McNevin MS, Lee PY, Bax TW. Martius flap: an adjunct for repair of complex, low rectovaginal fistula. *Am J Surg.* 2007;193:597–599.
198. Milito G, Lisi G, Venditti D, Campanelli M, Aronadio E, Grande M. Surgical treatment of rectovaginal fistula in Crohn's disease: a tertiary center experience. *Surg Technol Int.* 2017;30:113–116.
199. Remzi FH, El Gazzaz G, Kiran RP, Kirat HT, Fazio VW. Outcomes following Turnbull-Cutait abdominoperineal pull-through compared with coloanal anastomosis. *Br J Surg.* 2009;96:424–429.
200. van der Hagen SJ, Soeters PB, Baeten CG, van Gemert WG. Laparoscopic fistula excision and omentoplasty for high rectovaginal fistulas: a prospective study of 40 patients. *Int J Colorectal Dis.* 2011;26:1463–1467.
201. Watanabe J, Ota M, Kawaguchi D, et al. Incidence and risk factors for rectovaginal fistula after low anterior resection for rectal cancer. *Int J Colorectal Dis.* 2015;30:1659–1666.
202. Nowacki MP, Szawlowski AW, Borkowski A. Parks' coloanal sleeve anastomosis for treatment of postirradiation rectovaginal fistula. *Dis Colon Rectum.* 1986;29:817–820.
203. Nowacki MP. Ten years of experience with Parks' coloanal sleeve anastomosis for the treatment of post-irradiation rectovaginal fistula. *Eur J Surg Oncol.* 1991;17:563–566.
204. Patsouras D, Yassin NA, Phillips RK. Clinical outcomes of coloanal pull-through procedure for complex rectal conditions. *Colorectal Dis.* 2014;16:253–258.
205. Karakayali FY, Tezcaner T, Ozcelik U, Moray G. The outcomes of ultralow anterior resection or an abdominoperineal pull-through resection and coloanal anastomosis for radiation-induced recto-vaginal fistula patients. *J Gastrointest Surg.* 2016;20:994–1001.
206. Zhong Q, Yuan Z, Ma T, et al. Restorative resection of radiation rectovaginal fistula can better relieve anorectal symptoms than colostomy only. *World J Surg Oncol.* 2017;15:37.
207. Guidi L, Ratto C, Semeraro S, et al. Combined therapy with infliximab and seton drainage for perianal fistulizing Crohn's disease with anal endosonographic monitoring: a single-centre experience. *Tech Coloproctol.* 2008;12:111–117.
208. Topstad DR, Panaccione R, Heine JA, Johnson DR, MacLean AR, Buie WD. Combined seton placement, infliximab infusion, and maintenance immunosuppressives improve healing rate in fistulizing anorectal Crohn's disease: a single center experience. *Dis Colon Rectum.* 2003;46:577–583.
209. Sands BE, Anderson FH, Bernstein CN, et al. Infliximab maintenance therapy for fistulizing Crohn's disease. *N Engl J Med.* 2004;350:876–885.
210. Hanauer SB, Sandborn WJ, Rutgeerts P, et al. Human anti-tumor necrosis factor monoclonal antibody (adalimumab) in Crohn's disease: the CLASSIC-I trial. *Gastroenterology.* 2006;130:323–333.
211. Korelitz BI, Present DH. Favorable effect of 6-mercaptopurine on fistulae of Crohn's disease. *Dig Dis Sci.* 1985;30:58–64.
212. Present DH, Lichtiger S. Efficacy of cyclosporine in treatment of fistula of Crohn's disease. *Dig Dis Sci.* 1994;39:374–380.
213. Sandborn WJ, Rutgeerts P, Enns R, et al. Adalimumab induction therapy for Crohn disease previously treated with infliximab: a randomized trial. *Ann Intern Med.* 2007;146:829–838.
214. Colombel JF, Sandborn WJ, Rutgeerts P, et al. Adalimumab for maintenance of clinical response and remission in patients with Crohn's disease: the CHARM trial. *Gastroenterology.* 2007;132:52–65.
215. Schreiber S, Lawrance IC, Thomsen OØ, Hanauer SB, Bloomfield R, Sandborn WJ. Randomised clinical trial: certolizumab pegol for fistulas in Crohn's disease—subgroup results from a placebo-controlled study. *Aliment Pharmacol Ther.* 2011;33:185–193.
216. Takesue Y, Ohge H, Yokoyama T, Murakami Y, Imamura Y, Sueda T. Long-term results of seton drainage on complex anal fistulae in patients with Crohn's disease. *J Gastroenterol.* 2002;37:912–915.

Copyright © The American Society of Colon & Rectal Surgeons, Inc. Unauthorized reproduction of this article is prohibited.

217. Gecse KB, Bemelman W, Kamm MA, et al; World Gastroenterology Organization, International Organisation for Inflammatory Bowel Diseases IOIBD, European Society of Coloproctology and Robarts Clinical Trials; World Gastroenterology Organization International Organisation for Inflammatory Bowel Diseases IOIBD European Society of Coloproctology and Robarts Clinical Trials. A global consensus on the classification, diagnosis and multidisciplinary treatment of perianal fistulising Crohn's disease. *Gut.* 2014;63: 1381–1392.
218. Galandiuk S, Kimberling J, Al-Mishlab TG, Stromberg AJ. Perianal Crohn disease: predictors of need for permanent diversion. *Ann Surg.* 2005;241:796–801.
219. Gu J, Valente MA, Remzi FH, Stocchi L. Factors affecting the fate of faecal diversion in patients with perianal Crohn's disease. *Colorectal Dis.* 2015;17:66–72.
220. Löffler T, Welsch T, Mühl S, Hinz U, Schmidt J, Kienle P. Long-term success rate after surgical treatment of anorectal and rectovaginal fistulas in Crohn's disease. *Int J Colorectal Dis.* 2009;24:521–526.
221. Sauk J, Nguyen D, Yajnik V, et al. Natural history of perianal Crohn's disease after fecal diversion. *Inflamm Bowel Dis.* 2014;20:2260–2265.
222. Norton C, Dibley LB, Bassett P. Faecal incontinence in inflammatory bowel disease: associations and effect on quality of life. *J Crohns Colitis.* 2013;7:e302–e311.
223. McKee RF, Keenan RA. Perianal Crohn's disease—is it all bad news? *Dis Colon Rectum.* 1996;39:136–142.
224. Parks AG, Stitz RW. The treatment of high fistula-in-ano. *Dis Colon Rectum.* 1976;19:487–499.
225. Eitan A, Koliada M, Bickel A. The use of the loose seton technique as a definitive treatment for recurrent and persistent high trans-sphincteric anal fistulas: a long-term outcome. *J Gastrointest Surg.* 2009;13:1116–1119.
226. Galis-Rozen E, Tulchinsky H, Rosen A, et al. Long-term outcome of loose seton for complex anal fistula: a two-centre study of patients with and without Crohn's disease. *Colorectal Dis.* 2010;12:358–362.
227. Regueiro M, Mardini H. Treatment of perianal fistulizing Crohn's disease with infliximab alone or as an adjunct to exam under anesthesia with seton placement. *Inflamm Bowel Dis.* 2003;9:98–103.
228. de Groof EJ, Sahami S, Lucas C, Ponsioen CY, Bemelman WA, Buskens CJ. Treatment of perianal fistula in Crohn's disease: a systematic review and meta-analysis comparing seton drainage and anti-tumour necrosis factor treatment. *Colorectal Dis.* 2016;18:667–675.
229. Yang BL, Chen YG, Gu YF, et al. Long-term outcome of infliximab combined with surgery for perianal fistulizing Crohn's disease. *World J Gastroenterol.* 2015;21:2475–2482.
230. Sebastian S, Black C, Pugliese D, et al. The role of multimodal treatment in Crohn's disease patients with perianal fistula: a multicentre retrospective cohort study. *Aliment Pharmacol Ther.* 2018;48:941–950.
231. Schwartz DA, Wang A, Ozbay B, et al. Comparison of health care utilization and costs between patients with perianal fistulizing Crohn's disease treated with biologics with or without previous seton placement. *Inflamm Bowel Dis.* 2017;23:1860–1866.
232. Jeon M, Song K, Koo J, Kim S. Evaluation of a seton procedure combined with infliximab therapy (early vs. late) in perianal fistula with Crohn disease. *Ann Coloproctol.* 2019;35: 249–253.
233. Tanaka S, Matsuo K, Sasaki T, et al. Clinical advantages of combined seton placement and infliximab maintenance therapy for perianal fistulizing Crohn's disease: when and how were the seton drains removed? *Hepatogastroenterology.* 2010;57:3–7.
234. Sands BE, Blank MA, Diamond RH, Barrett JP, Van Deventer SJ. Maintenance infliximab does not result in increased abscess development in fistulizing Crohn's disease: results from the ACCENT II study. *Aliment Pharmacol Ther.* 2006;23:1127–1136.
235. Morrison JG, Gathright JB Jr, Ray JE, Ferrari BT, Hicks TC, Timmcke AE. Surgical management of anorectal fistulas in Crohn's disease. *Dis Colon Rectum.* 1989;32:492–496.
236. Williams JG, Rothenberger DA, Nemer FD, Goldberg SM. Fistula-in-ano in Crohn's disease. Results of aggressive surgical treatment. *Dis Colon Rectum.* 1991;34:378–384.
237. Nordgren S, Fasth S, Hultén L. Anal fistulas in Crohn's disease: incidence and outcome of surgical treatment. *Int J Colorectal Dis.* 1992;7:214–218.
238. Sohn N, Korelitz BI, Weinstein MA. Anorectal Crohn's disease: definitive surgery for fistulas and recurrent abscesses. *Am J Surg.* 1980;139:394–397.
239. van Koperen PJ, Safiruddin F, Bemelman WA, Slors JF. Outcome of surgical treatment for fistula in ano in Crohn's disease. *Br J Surg.* 2009;96:675–679.
240. van Koperen PJ, Wind J, Bemelman WA, Bakx R, Reitsma JB, Slors JF. Long-term functional outcome and risk factors for recurrence after surgical treatment for low and high perianal fistulas of cryptoglandular origin. *Dis Colon Rectum.* 2008;51:1475–1481.
241. Mardini HE, Schwartz DA. Treatment of perianal fistula and abscess: Crohn's and non-Crohn's. *Curr Treat Options Gastroenterol.* 2007;10:211–220.
242. Makowiec F, Jehle EC, Becker HD, Starlinger M. Perianal abscess in Crohn's disease. *Dis Colon Rectum.* 1997;40:443–450.
243. Gingold DS, Murrell ZA, Fleshner PR. A prospective evaluation of the ligation of the intersphincteric tract procedure for complex anal fistula in patients with Crohn's disease. *Ann Surg.* 2014;260:1057–1061.
244. Kamiński JP, Zaghiyan K, Fleshner P. Increasing experience of ligation of the intersphincteric fistula tract for patients with Crohn's disease: what have we learned? *Colorectal Dis.* 2017;19:750–755.
245. Gionchetti P, Dignass A, Danese S, et al; ECCO. 3rd European evidence-based consensus on the diagnosis and management of Crohn's disease 2016: part 2: surgical management and special situations. *J Crohns Colitis.* 2017;11:135–149.
246. Singh S, Ding NS, Mathis KL, et al. Systematic review with meta-analysis: faecal diversion for management of perianal Crohn's disease. *Aliment Pharmacol Ther.* 2015;42:783–792.
247. Bafford AC, Latushko A, Hansraj N, Jambaulikar G, Ghazi LJ. The use of temporary fecal diversion in colonic and perianal Crohn's disease does not improve outcomes. *Dig Dis Sci.* 2017;62:2079–2086.
248. Cho YB, Lee WY, Park KJ, Kim M, Yoo HW, Yu CS. Autologous adipose tissue-derived stem cells for the treatment of Crohn's fistula: a phase I clinical study. *Cell Transplant.* 2013;22: 279–285.
249. Dietz AB, Dozois EJ, Fletcher JG, et al. Autologous mesenchymal stem cells, applied in a bioabsorbable matrix, for

Copyright © The American Society of Colon & Rectal Surgeons, Inc. Unauthorized reproduction of this article is prohibited.

treatment of perianal fistulas in patients with Crohn's disease. *Gastroenterology.* 2017;153:59–62.e2.
250. García-Olmo D, García-Arranz M, Herreros D, Pascual I, Peiro C, Rodríguez-Montes JA. A phase I clinical trial of the treatment of Crohn's fistula by adipose mesenchymal stem cell transplantation. *Dis Colon Rectum.* 2005;48:1416–1423.
251. Garcia-Olmo D, Herreros D, Pascual I, et al. Expanded adipose-derived stem cells for the treatment of complex perianal fistula: a phase II clinical trial. *Dis Colon Rectum.* 2009;52: 79–86.
252. Molendijk I, Bonsing BA, Roelofs H, et al. Allogeneic bone marrow-derived mesenchymal stromal cells promote healing of refractory perianal fistulas in patients with Crohn's disease. *Gastroenterology.* 2015;149:918–27.e6.
253. Cho YB, Park KJ, Yoon SN, et al. Long-term results of adipose-derived stem cell therapy for the treatment of Crohn's fistula. *Stem Cells Transl Med.* 2015;4:532–537.
254. de la Portilla F, Alba F, García-Olmo D, Herrerías JM, González FX, Galindo A. Expanded allogeneic adipose-derived stem cells (eASCs) for the treatment of complex perianal fistula in Crohn's disease: results from a multicenter phase I/IIa clinical trial. *Int J Colorectal Dis.* 2013;28:313–323.
255. Panés J, García-Olmo D, Van Assche G, et al; ADMIRE CD Study Group Collaborators. Expanded allogeneic adipose-derived mesenchymal stem cells (Cx601) for complex perianal fistulas in Crohn's disease: a phase 3 randomised, double-blind controlled trial. *Lancet.* 2016;388:1281–1290.
256. Ciccocioppo R, Bernardo ME, Sgarella A, et al. Autologous bone marrow-derived mesenchymal stromal cells in the treatment of fistulising Crohn's disease. *Gut.* 2011;60:788–798.
257. Lee WY, Park KJ, Cho YB, et al. Autologous adipose tissue-derived stem cells treatment demonstrated favorable and sustainable therapeutic effect for Crohn's fistula. *Stem Cells.* 2013;31:2575–2581.
258. Panés J, García-Olmo D, Van Assche G, et al; ADMIRE CD Study Group Collaborators. Long-term efficacy and safety of stem cell therapy (Cx601) for complex perianal fistulas in patients with Crohn's disease. *Gastroenterology.* 2018;154:1334–1342.e4.
259. Lightner AL, Wang Z, Zubair AC, Dozois EJ. A Systematic review and meta-analysis of mesenchymal stem cell injections for the treatment of perianal Crohn's disease: progress made and future directions. *Dis Colon Rectum.* 2018;61:629–640.
260. García-Olmo D, García-Arranz M, García LG, et al. Autologous stem cell transplantation for treatment of rectovaginal fistula in perianal Crohn's disease: a new cell-based therapy. *Int J Colorectal Dis.* 2003;18:451–454.
261. Barnhoorn MC, Wasser MNJM, Roelofs H, et al. Long-term evaluation of allogeneic bone marrow-derived mesenchymal stromal cell therapy for Crohn's disease perianal fistulas. *J Crohns Colitis.* 2020;14:64–70.
262. Castro-Poceiro J, Fernández-Clotet A, Panés J. Mesenchymal stromal cells in the treatment of perianal fistulas in Crohn's disease. *Immunotherapy.* 2018;10:1203–1217.
263. Dozois EJ, Lightner AL, Mathis KL, et al. Early results of a phase I trial using an adipose-derived mesenchymal stem cell-coated fistula plug for the treatment of transsphincteric cryptoglandular fistulas. *Dis Colon Rectum.* 2019;62:615–622.
264. Ascanelli S, Zamboni P, Campioni D, et al. Efficacy and safety of treatment of complex idiopathic fistula-in-ano using autologous centrifuged adipose tissue containing progenitor cells: a randomized controlled trial. *Dis Colon Rectum.* 2021;64:1276–1285.
265. Maciel Gutiérrez VM, Gutiérrez Guillen SG, Centeno Flores MW, et al. Safety of allogeneic adipose tissue-derived mesenchymal stem cells for the treatment of complex perianal fistulas not associated with Crohn's disease: a phase I clinical trial. *Dis Colon Rectum.* 2021;64:328–334.
266. Garcia-Arranz M, Garcia-Olmo D, Herreros MD, et al; FISPAC Collaborative Group. Autologous adipose-derived stem cells for the treatment of complex cryptoglandular perianal fistula: a randomized clinical trial with long-term follow-up. *Stem Cells Transl Med.* 2020;9:295–301.
267. Zhang Y, Ni M, Zhou C, et al. Autologous adipose-derived stem cells for the treatment of complex cryptoglandular perianal fistula: a prospective case-control study. *Stem Cell Res Ther.* 2020;11:475.

Copyright © The American Society of Colon & Rectal Surgeons, Inc. Unauthorized reproduction of this article is prohibited.